

ALK-positive Large B-cell Lymphoma: A Clinicopathologic Retrospective Descriptive Study from a Tertiary Care Cancer Centre in India

JAYASUDHA ARUNDHATHI VASUDEVAN¹, REKHA A NAIR², PRIYA MARY JACOB³, CM SIMI⁴, NP PRAKASH⁵, ALEYAMMA MATHEW⁶



ABSTRACT

Introduction: Anaplastic Lymphoma Kinase (ALK) positive Large B-Cell Lymphoma (ALK+ LBCL) is a very rare aggressive B-cell lymphoma presenting significant diagnostic challenges due to their rarity and unique immunophenotypic features. ALK is a tyrosine kinase receptor and is expressed by ALK+ LBCL due to ALK rearrangement.

Aim: To analyse the histopathological features including morphology and immunophenotype, clinical details, pattern of care, progression-free survival (PFS) and overall survival of cases diagnosed as ALK+ LBCL.

Materials and Methods: This clinicopathological retrospective descriptive study was conducted in the Department of Pathology at a Tertiary Care Cancer Centre, Thiruvananthapuram, Kerala, India. The duration of the study was six months, from January 2022 to June 2022. All the cases of ALK+ LBCL were diagnosed over a period of 10 years, from January 1st 2010 to December 31st 2020. The cases of LBCL diagnosed during the 10 year period were reviewed. Clinical details were obtained from the case sheets of the cases diagnosed as ALK+ LBCL and summarised. Data collection variables included age, sex, stage, nodal and extranodal status, bone marrow, Central Nervous System (CNS) involvement, haemoglobin, Total Leukocyte Count (TLC) and platelet count, Lactate Dehydrogenase (LDH)

value, performance status, date of diagnosis, date of treatment started, date of progression, date of last follow-up, date of death (if dead). Review of Haematoxylin & Eosin (H&E) sections and immunohistochemical slides were done and observations were recorded. Descriptive statistics was used to summarise the basic features of the dataset and Kaplan-Meier method was used for calculation of survival.

Results: The age of study participants was ranged from 16-56 years. During the 10 year period, LBCL accounted for 2415 cases. Among these, ALK+ LBCL constituted 6 (0.25%) cases. There was a male predilection (n=5). Blood counts were normal except for anaemia in three patients. LDH was raised in all the patients. Advanced stage disease was present in two patients. Histopathologically, tumour cells in all the cases showed plasmablastic morphology. Immunohistochemistry (IHC) revealed plasma cell immunophenotype and positivity for ALK in all the cases. Cytokeratin (CK) and Epithelial Membrane Antigen (EMA) were positive in three cases simulating carcinomas. Six year overall survival and progression free survival in the present study was 50% and 33.3%, respectively.

Conclusion: Careful interpretation of the morphology and immunophenotype is essential for diagnosis of ALK+ LBCL, as it can be easily misdiagnosed as a non haematological malignancy thus, affecting the treatment and prognosis in these patients.

Keywords: Anaplastic lymphoma kinase, Carcinoma, Frequency, Immunophenotype

INTRODUCTION

The ALK is a receptor tyrosine kinase playing important role in the development of brain and regulation of nerve cell proliferation [1]. ALK expression was initially found in Anaplastic Large Cell Lymphoma (ALCL) [2]. The ALK gene is also found to be mutated in other tumours also, like ALK+ LBCL, epithelioid fibrous histiocytoma, inflammatory myofibroblastic tumour, adenocarcinoma of lung etc., [3-6]. The first description of ALK+ LBCL was in 1997 [3]. It is an aggressive neoplasm of large B-cells and usually has a plasma cell phenotype. These tumours can also be mistaken for carcinomas as occasional cases show positivity for CK and EMA in combination with negative staining for LCA [7]. The most frequent genetic abnormality is t(2;17) resulting in Clathrin Heavy Chain (CLTC)-ALK fusion protein [7]. Disease has aggressive clinical course. Significantly longer survival is reported in those with localised disease [8]. The present study emphasises the importance of correlation of morphology with an optimal immunohistochemical panel for the accurate diagnosis of ALK+ LBCL and to avoid misdiagnosing it as non haematopoietic neoplasms. Data on ALK+ LBCL is mainly available as case reports, case series, few review and research articles and have highlighted

the rarity and the high possibility of pathological misdiagnosis because of its morphologic and immunophenotypic overlap with other haematopoietic and non haematopoietic neoplasms [8-28]. The present study adds to the existing number of cases to help in further understanding of clinicopathologic features, diagnosis and outcome of this rare entity. Aim of the present study was to study the morphology and immunophenotypic profile, clinical details, pattern of care, PFS and overall survival of patients diagnosed as ALK+ LBCL.

MATERIALS AND METHODS

This was a clinicopathological retrospective descriptive study was conducted in the Department of Pathology, Regional Cancer Centre, Thiruvananthapuram, Kerala, India. The duration of the study was six months, from January 2022 to June 2022. Period of study was for a duration of 10 years from January 2010 December 2020. The study was approved by Human Ethics Committee, letter number (HEC No. 29/22 dated 24th May 2022). The study was in accordance with the ethical standards of the responsible committee on human experimentation (Institutional) and with the Helsinki Declaration of 1964 as revised in 2013. Waiver of informed consent was approved

by HEC, as it was a retrospective study of six cases, involving only data collection and did not involve revealing the patient identity at any point of time.

Inclusion criteria: Cases of ALK+ LBCL, diagnosed in the centre during the study period were included in the study.

Exclusion criteria: Cases of ALK+ LBCL, whose slides and blocks could not be retrieved from the archives and the non registered cases were excluded from the study.

Study Procedure

The slides and blocks of selected cases were retrieved and reviewed. Case sheets of all the six cases were retrieved. The details of the cases were collected and entered into the proforma for analysis. Data collection variables included age, sex, stage, lymph node status, extranodal involvement, bone marrow, CNS involvement (neurological examination/ radiological examination/pathological study by stereotactic biopsy/lumbar puncture) [29], haemoglobin (reference range-females: 12.1-15.1 gm/dL, males: 13.8-17.2 gm/dL), TLC (reference range-4500-11,000 White Blood Cells (WBC)/mL), platelet count (reference range-1,50,000-4,50,000/mL), LDH value (reference range-120-246 u/L), performance status {measured by Eastern Cooperative Oncology Group (ECOG) scale} [30], date of diagnosis, date of treatment started, date of progression, date of last follow-up, date of death (if dead). Primary outcome was the spectrum of morphologic and immunohistochemical profile of cases diagnosed as ALK+ LBCL. Secondary outcome was the clinical scenario, progression- free and overall survival of the cases [31]. In order to reduce the lost to follow-up cases, the authors attempted to contact the patients through phone, and data were collected.

The IHC is a diagnostic laboratory technique used to detect specific antigens in tissues based on antigen-antibody recognition. It is important in diagnostic pathology for the diagnosis and classification of tumours. IHC is also important for identification of prognostic and predictive markers [32]. Immunophenotyping by IHC was done by automation in Ventana BenchMark XT. Panel of antibodies used for IHC include Cluster of Differentiation (CD) markers CD45 (clone 2B11-PD7/26, Dallas Area Kitefliers Organisation (DAKO), 1:500 dilution), CD20 {clone L26, DAKO, 1:50 dilution), CD79a (clone JCB117, DAKO, Ready-to-Use (RTU)), CD5 (clone 4C7, Biocare, 1:50 dilution), CD30 (clone Beryllium hydride2 (BeH2), DAKO, 1:50 dilution), CD138 (clone M115, DAKO, 1:50 dilution), CD38 (clone Epithelial (EP)135, PathnSitu, RTU), CK (clone AE1/AE3, DAKO, 1:100 dilution), EMA (clone E29, DAKO, 1:50 dilution), PAX5 (Paired box 5) (clone DAK-nuclear protein in the paired-box (PAX5), DAKO, RTU), Multiple Myeloma1 (MUM1) (clone MUM1p, DAKO, RTU), Ki-67 (Kiel-67) (clone MIB1, DAKO, 1:50 dilution), ALK (clone ALK-1, DAKO, 1:50 dilution), Kappa (clone L1C1, Biocare, 1:50 dilution), Lambda (clone N10/2, Biocare, 1:50 dilution), CyclinD1 (clone SP4, Biocare, 1:50 dilution) and CD56 (123C3, DAKO, RTU).

STATISTICAL ANALYSIS

Descriptive statistics such as mean, standard deviation, frequency and percentage were calculated. Kaplan-Meier method was used for calculating survival.

RESULTS

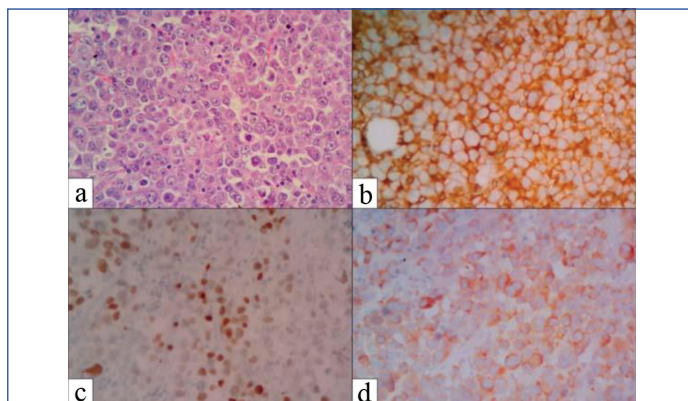
During the 10 years of period, around 2415 cases of LBCL were diagnosed in the cancer centre. Among these, ALK+ LBCL constituted 6 cases (0.25%). Clinical details are summarised in [Table/Fig-1]. Age ranged from 16-56 years. There was a male predominance 5 (83.33%) cases. Anaemia was present in four patients. TLC and platelet counts were within the normal range in all patients. LDH was raised in all patients and ranged from 546 u/L-1686 u/L. Advanced stage disease was seen in 2 (33.33%) patients. Among the two patients, one patient is alive with evidence of disease and the other patient died of disease. Bone marrow was uninvolved in all the cases.

Parameters	Case 1	Case 2	Case 3	Case 4	Case 5	Case 6
Age (years)	50	17	50	56	39	16
Sex	Female	Male	Male	Male	Male	Male
Stage	3B	2B	2B	4B	2B	2A
Extranodal	Nil	Nil	Nil	Liver	SI	Nil
Bone marrow	Nil	Nil	Nil	Nil	Nil	Nil
CNS	Nil	Nil	Nil	Nil	Nil	Nil
Haemoglobin (gm/dL)	9.9	12.8	13.9	9	7.7	14.9
Total count (Cells/mm ³)	10500	14600	7400	5300	6400	9300
Platelet count (Lakhs/mm ³)	4.5	4.37	3.28	6.24	4.08	2.4
LDH	1337	780	546	787	1686	601
PS	1	1	1	1	2	1
Outcome	Alive	Dead	Alive with disease	Dead	Dead	Alive

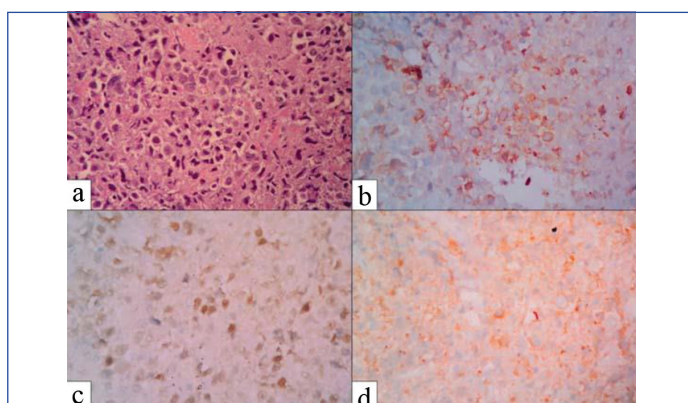
[Table/Fig-1]: Clinical details and outcome of the six cases of ALK+ LBCL. SI: Small intestine; CNS: Central nervous system; LDH: Lactate dehydrogenase; PS: Performance status

Histopathology of all the cases showed, large tumour cells with plasmablastic appearance and diffuse infiltrative growth patterns.

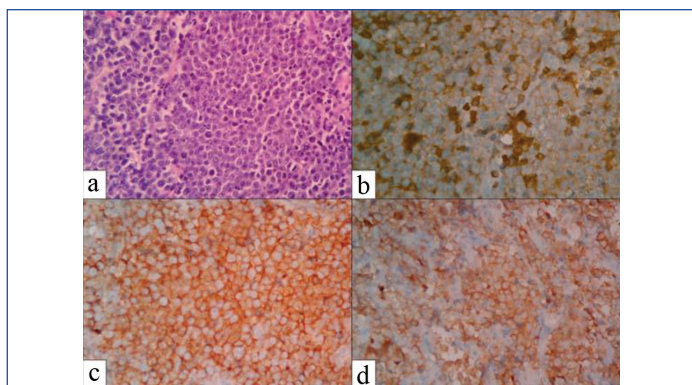
Analysis of IHC findings revealed that, tumour cells in all the cases were positive for ALK in a cytoplasmic granular pattern [Table/Fig-2-6]. The LCA was positive with varying intensity in five cases. CK was positive with varying intensity in three cases. CD20 was negative in all the cases. MUM1 and CD138 were positive in all the cases. Immunophenotype is summarised in [Table/Fig-7]. Cases three and four were challenging as tumour cells were focally weak positive to negative for LCA coupled with weak positivity for CK. Case 4 presented with epigastric mass and was positive for CK, EMA, c-Kit and negative for LCA by IHC. Kappa lambda light chain staining was done in four cases and showed light chain restriction in three cases.



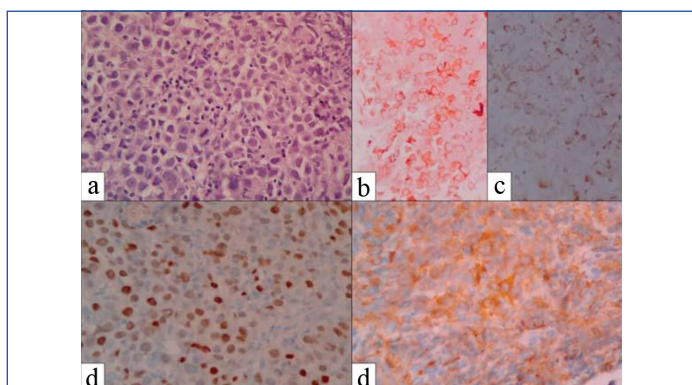
[Table/Fig-2]: Case 1: a) Atypical lymphoid cells with plasmablastic appearance. (H&E, x400); b) Membrane positivity for Life Cycle Assessment (LCA). (IHC, x400); c) Nuclear positivity for MUM1. (IHC, x400); d) Cytoplasmic positivity for ALK. (IHC, x400).



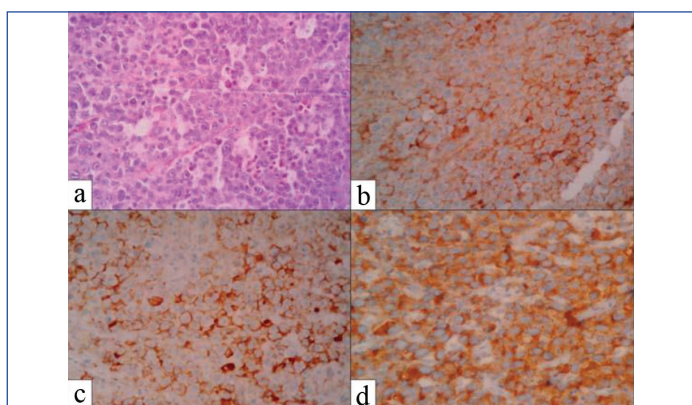
[Table/Fig-3]: Case 2: a) Atypical lymphoid cells showing plasmablastic appearance. (H&E, x400); b) Tumour cells are focally positive for CK. (IHC, x400); c) EMA positive. (IHC, x400); d) ALK positive (IHC, x400).



[Table/Fig-4]: Case 3: a) Tumour cells arranged diffusely. (H&E, x400); b) Tumour cells are positive for LCA. (IHC, x400); c) CD138 positive. (IHC, x400); d) ALK positive. (IHC, x400).



[Table/Fig-5]: Case 4: a) Atypical lymphoid cells with plasmablastic features. (H&E, x400); b) Tumour cells are focally positive for CK. (IHC, x400); c) EMA positive. (IHC, x400); d) MUM1 positive. (IHC, x400); e) ALK positive (IHC, x400).



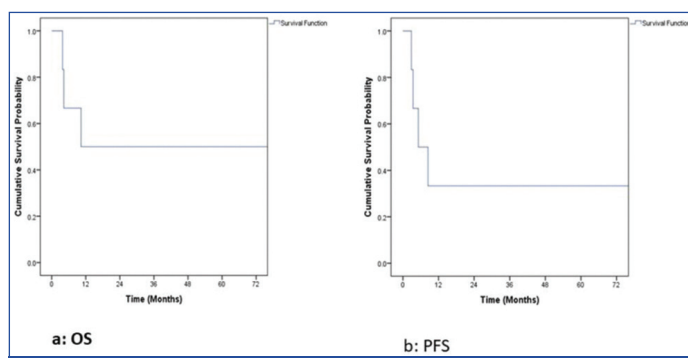
[Table/Fig-6]: Case 6: a) Atypical lymphoid cells showing plasmablastic appearance. (H&E, x400); b) Tumour cells are positive for EMA. (IHC, x400); c) CD138 positive. (IHC, x400); d) ALK positive. (IHC, x400)

IHC marker	Case 1	Case 2	Case 3	Case 4	Case 5	Case 6
CD45	+	+	Weak+	-	+	+
CK	-	Focal+	Weak+	+	Not done	-
EMA	Not done	Focal+	Not done	+	Not done	Focal+
CD20	-	-	-	-	-	-
CD79a	-	-	-	Focal+	Not done	-
PAX5	Not done	-	Dim+	Dim+	Not done	-
CD5	-	-	-	-	-	-
CD30	-	-	-	-	-	-
MUM1	+	+	+	+	+	+
Ki-67	80%	70%	90-95%	40%	90%	70%
CD138	Focal+	+	+	+	+	Focal+
CD38	Focal+	+	Not done	Not done	+	Not done

ALK	+	+	+	+	+	+
Light chain restriction	+, kappa	+, lambda	+, lambda	-	Not done	Not done
Cyclin D1	-	-	-	-	-	-
CD56	-	-	-	-	-	-

[Table/Fig-7]: Immunophenotype of the six cases of ALK+ LBCL. +: positive; -: negative; CK: Cytokeratin; CD: Cluster of differentiation; EMA: Epithelial membrane antigen; PAX5: Paired box 5; MUM1: Multiple myeloma 1; Ki-67: Kiel-67; ALK: Anaplastic Lymphoma Kinase

Patients were primarily treated by Cyclophosphamide, Hydroxydaunorubicin, Oncovin, Prednisolone (CHOP) regimen. Relapsed and refractory cases were managed by Dexamethasone, High Dose Cytarabine, Cisplatin (DHAP), Ifosfamide, Carboplatin, Etoposide (ICE) regimens according to the age and performance status of individuals. Follow-up at four years was 100% and at five years was 83.3%. Median follow-up period was 75 months. Six-year overall survival was 50% (SE=0.20) and PFS was 33.3% (SE=0.19) [Table/Fig-8 a,b].



[Table/Fig-8]: a) Kaplan-Meier curve showing the overall survival. b) Kaplan-Meier curve showing the PFS.

DISCUSSION

The ALK+ LBCL is rare and accounts for less than 1% of LBCL [7]. The frequency of ALK+ LBCL is similar to that mentioned in literature [7]. Median age reported in literature, is 43 years with age range of 9-85 years [7]. Age range mentioned in the present study, is similar to that in other studies [9-14]. One third of cases of ALK+ LBCL are reported in paediatric age group [7]. ALK+ LBCL shows a male predilection, which was also seen in the present study [7]. ALK+ LBCL are primarily a nodal disease [7]. All patients had primary involvement of nodes. Among the extranodal sites, upper airway is the most affected site [10]. Other sites includes bone, gastrointestinal tract, spleen, liver and skin [7, 10]. Case 4 and 5 showed contiguous involvement of liver and small intestine, respectively. Bone marrow was uninvolved in all the six cases. Bone marrow is reported to be involved in 25% of cases of ALK+ LBCL but none of the cases in the present study had bone marrow involvement [7]. Another study showed bone marrow infiltration in 33% of patients [10]. Although, patients are more likely to present with advanced stage disease (stage 3/4), advanced disease was present in 2 (33.33%) cases.

Advanced stage disease is reported in around 60% of patients [7,10]. Morphology of tumour cells in all the cases showed a plasmablastic appearance. IHC also showed plasma cell phenotype in all the cases. Cases 2, 3 and 4 mimicked non haematopoietic tumours as tumour cells were weakly positive for CK and were focally positive to negative for LCA. Case 4 presented with epigastric mass and was positive for CK, EMA, c-Kit and negative for LCA by IHC, thus, initially suggesting the diagnosis of epithelioid gastrointestinal stromal tumour. These cases can be easily misdiagnosed morphologically and immunophenotypically as non haematopoietic neoplasms or other haematopoietic neoplasms with a limited panel of IHC markers [7,10-14]. Comparison of IHC of the present study and similar other published studies is given in [Table/Fig-9] [9,12,13,17,18,26].

IHC marker	Present study. N/T (%)	Chandramohan J et al., (India 2022) [13] N/T (%)	Pan Z et al., (USA, 2017) [9] N/T (%)	Beltran B et al., (Peru,2009) [12] N/T (%)	Gascoyne RD et al., (France, 2003) [18] N/T (%)	Jiang XN et al., (China, 2017) [26] N/T (%)	Reichard KK et al., (USA, 2007) [17] N/T (%)
CD45	5/6 (83.3)	3/3 (100)	23/24 (95.8)	4/4 (100)	ND	4/7 (57.1)	4/4 (100)
CK	3/5 (60)	1/7 (14.3)	1/14 (7.1)	ND	ND	2/8 (25)	1/4 (25)
EMA	3/3 (100)	3/3 (100)	16/22 (72.2)	3/3 (100)	6/6 (100)	11/14 (78.6)	4/4 (100)
CD138	6/6 (100)	11/11 (100)	24/25 (96)	ND	6/6 (100)	9/11 (81.8)	4/4 (100)
CD38	3/3 (100)	ND	ND	ND	ND	3/9 (33.3)	1/4 (25)
MUM1	6/6 (100)	11/11 (100)	14/14 (100)	4/4 (100)	ND	8/9 (88.9)	ND
ALK	6/6 (100)	11/11 (100)	26/26 (100)	4/4 (100)	6/6 (100)	17/17 (100)	4/4 (100)
Light chain restriction	3/4 (75)	ND	15/18 (83)	3/4 (75)	4/6 (66.7)	17/17 (100)	4/4 (100)
Cyclin D1	0/6 (0)	2/6 (33.3)	ND	ND	ND	ND	ND
Ki-67	40%-95%	65-90%	ND	ND	ND	60-90%	50-80%
CD30	0/6 (0)	2/10 (20)	1/23 (4.3)	0/4 (0)	0/6 (0)	1/15 (6.67)	0/4 (0)
CD5	0/6 (0)	ND	ND	ND	ND	ND	ND
PAX5	2/4 (50)	2/4 (50)	5/18 (2.8)	ND	ND	ND	ND
CD79a	1/5 (20)	2/6 (33.3)	7/23 (3)	1/4 (25)	0/6 (0)	3/9 (33.3)	2/4 (50)
CD20	0/6 (0)	0/11 (0)	0/24 (0)	0/4 (0)	0/6 (0)	2/15 (13.3)	1/4 (25)
CD4	ND	4/4 (100)	8/12 (66.7)	0/4 (0)	4/6 (66.7)	2/9 (22.2)	4/4 (100)
EBV	ND	0/4 (0)	ND	0/4 (0)	ND	ND	ND
CD56	ND	ND	ND	0/4 (0)	ND	ND	ND
HHV-8	ND	ND	ND	0/2 (0)	ND	ND	ND

[Table/Fig-9]: Comparison of IHC findings of the present study and few other published studies [9,12,13,17,18,26].

(N/T=Number of cases positive for the IHC marker/total number of cases tested; ND: Not done); HHV: Human herpesvirus

Differential diagnosis of these tumours includes metastatic carcinomas, LBCL [Diffuse large B cell lymphoma (DLBCL)-anaplastic variant, Primary Effusion Lymphoma (PEL), plasmablastic lymphoma} plasmacytoma, Anaplastic Large Cell Lymphoma (ALCL) of T-cell origin [7]. Occasional cases of ALK+ LBCL are positive for CK, EMA and negative for LCA thus, simulating carcinomas [7]. MUM1 positivity in ALK+ LBCL will help in differentiating from carcinomas in these instances. Carcinomas are MUM1 negative [13]. Napsin A which is a marker of lung and ovarian adenocarcinomas can also be positive in ALK+ LBCL. A small subset of ALK positive lung adenocarcinomas, further add to the diagnostic difficulty. All the documented cases of napsin positive ALK+ LBCL are LCA positive [15,16]. DLBCL anaplastic variant express pan B-cell lineage antigens and is negative for ALK [7]. PEL usually present clinically as serous effusions and is universally associated with HHV-8 and usually occurs in immunodeficiency settings [7,13]. They express LCA, but lack pan B cell lineage antigens. Plasma cell markers are often positive by IHC. Tumour cells are positive for HHV-8 and negative for ALK [7,13]. Tumour cells are also positive for Epstein-Barr Encoding Region (EBER) by in-situ hybridisation. ALK+ LBCL usually occur in immunocompetent individuals and is negative for EBER and HHV-8 [7]. Plasmablastic Lymphoma (PBL) mostly occurs in association with Human Immunodeficiency Virus (HIV) infection. It is a high grade lymphoma with plasmablastic features morphologically and immunophenotypically, negative for ALK and express EBER by in-situ hybridisation [7,33,34]. Plasmacytoma with plasmablastic morphology can simulate ALK+ LBCL but, ALK is negative in plasmacytoma. Plasmacytoma is also characterised by distinctive clinical, biochemical and radiology findings. Demonstration of molecular alteration t(11;14) in a tumour with plasmablastic features is diagnostic of plasmacytoma [35]. ALK positive ALCL of T-cell origin is CD30 strongly positive. ALK+ LBCL are negative for T-cell lineage markers and is negative for CD30 although, focal weak staining of CD30 is reported [7].

Six-year overall survival was 50% and PFS was 33.3%. The median overall survival of patients with advanced stage disease is reported to be 11 months [17]. Morgan EA and Nascimento AF, reported five-year survival rate of 25% with a median survival of 12 months [11]. Pan Z et al., reported five year overall survival of 34% and

median survival of 1.83 years [9]. Castillo JJ et al., reported five year overall survival of 28% [10]. Another study showed a median overall survival of nine months [14]. Improved overall survival and PFS were noted in the present study but, statistical significance cannot be assessed due to limited number of cases.

Limitation(s)

Limitation of the study was that, molecular studies were not done and no statistical significance can be carried out due to the small sample size of the study.

CONCLUSION(S)

The ALK+ LBCL are a very rare clinically aggressive B cell lymphoma, which usually displays plasmablastic morphology and plasma cell immunophenotype. Awareness of this rare entity is extremely important, as it can be easily misdiagnosed as a non haematopoietic neoplasm due to its unique immunophenotypic profile.

REFERENCES

- Iwahara T, Fujimoto J, Wen D, Cupples R, Bucay N, Arakawa T, et al. Molecular characterization of ALK, a receptor tyrosine kinase expressed specifically in the nervous system. *Oncogene*. 1997;14:439-49.
- Shiota M, Nakamura S, Ichinohasama R, Abe M, Akagi T, Takeshita M, et al. Anaplastic large cell lymphomas expressing the novel chimeric protein p80NPM/ALK: a distinct clinicopathologic entity. *Blood*. 1995;86:1954-60.
- Delsol G, Lamant L, Mariamé B, Pulford K, Dastugue N, Brousset P, et al. A new subtype of large B-cell lymphoma expressing the ALK kinase and lacking the 2;5 translocation. *Blood*. 1997;89:1483-90.
- Doyle LA, Marino-Enriquez A, Fletcher CD, Hornick JL. ALK rearrangement and overexpression in epithelioid fibrous histiocytoma. *Mod Pathol*. 2015;28:904-12.
- Cook JR, Dehner LP, Collins MH, Ma Z, Morris SW, Coffin CM, et al. Anaplastic lymphoma kinase (ALK) expression in the inflammatory myofibroblastic tumor: a comparative immunohistochemical study. *Am J Surg Pathol*. 2001;25(11):1364-71.
- Inamura K, Takeuchi K, Togashi Y, Nomura K, Ninomiya H, Okui M, et al. EML4-ALK fusion is linked to histological characteristics in a subset of lung cancers. *J Thorac Oncol*. 2008;3:13-17.
- Swerdlow SH, Campo E, Harris NL, Jaffe ES, Pileri SA, Stein H, et al. eds. WHO Classification of tumours of haematopoietic and lymphoid tissues. Revised 4th ed. Lyon, France: International Agency for Research on Cancer; 2017. Pp. 319-20.
- Laurent C, Do C, Gascoyne RD, Lamant L, Ysebaert L, Laurent G, et al. Anaplastic lymphoma kinase-positive diffuse large B-cell lymphoma: a rare clinicopathologic entity with poor prognosis [published correction appears in *J Clin Oncol*. 2010;28(1):182]. *J Clin Oncol*. 2009;27:4211-16.

- [9] Pan Z, Hu S, Li M, Zhou Y, Kim YS, Reddy V, et al. ALK-positive Large B-cell Lymphoma: A clinicopathologic study of 26 cases with review of additional 108 cases in the literature. *Am J Surg Pathol*. 2017;41:25-38.
- [10] Castillo JJ, Beltran BE, Malpica L, Marques-Piubelli ML, Miranda RN. Anaplastic lymphoma kinase-positive large B-cell lymphoma (ALK+LBCL): a systematic review of clinicopathological features and management. *Leuk Lymphoma*. 2021;62:2845-53.
- [11] Morgan EA, Nascimento AF. Anaplastic lymphoma kinase-positive large B-cell lymphoma: an underrecognized aggressive lymphoma. *Adv Hematol*. 2012;2012:529572.
- [12] Beltran B, Castillo J, Salas R, Quiñones P, Morales D, Hurtado F, et al. ALK-positive diffuse large B-cell lymphoma: report of four cases and review of the literature. *J Hematol Oncol*. 2009;2:11.
- [13] Chandramohan J, Ganapule G, Sigamani E, George B, Korula A, Manipadam MT. ALK-positive large B-cell lymphomas: A clinicopathologic study. *Indian J Pathol Microbiol*. 2022;65:381-86.
- [14] Vanidassane I, Gogia A, Mallick S. Adult ALK-positive diffuse large B-cell lymphoma: A limited institutional experience. *Indian J Cancer*. 2019;56:373-74.
- [15] Nam SJ, Kim S, Kim JE, Lim MS, Elenitoba-Johnson KS, Kim CW, et al. Aberrant expression of napsin A in a subset of malignant lymphomas. *Histol Histopathol*. 2016;31:213-21.
- [16] Jain D, Mallick SR, Singh V, Singh G, Mathur SR, Sharma MC. Napsin A expression in anaplastic lymphoma Kinase-positive diffuse large B-cell lymphoma: A diagnostic pitfall. *Appl Immunohistochem Mol Morphol*. 2016;24:e34-40.
- [17] Reichard KK, McKenna RW, Kroft SH. ALK-positive diffuse large B-cell lymphoma: report of four cases and review of the literature. *Mod Pathol*. 2007;20:310-19.
- [18] Gascoyne RD, Lamant L, Martin-Subero JI, Lestou VS, Harris NL, Müller-Hermelink HK, et al. ALK-positive diffuse large B-cell lymphoma is associated with Clathrin-ALK rearrangements: report of 6 cases. *Blood*. 2003;102:2568-73.
- [19] Subramaniam A, Gnanasekaran D, Suruliraj S, Chinnusamy P. Anaplastic Lymphoma Kinase positive large B cell lymphoma of ileocaecal mesentery: A case report. *Indian J Pathol Microbiol*. 2020;63:615-17.
- [20] Chowdhury Z. Anaplastic lymphoma kinase positive Large B-Cell Lymphoma: diagnostic perils and pitfalls, an underrecognized entity. *Cureus*. 2021;13:e16882.
- [21] De Paepe P, Baens M, van Krieken H, Verhasselt B, Stul M, Simons A, et al. ALK activation by the CLTC-ALK fusion is a recurrent event in large B-cell lymphoma. *Blood*. 2003;102:2638-41.
- [22] Gesk S, Gascoyne RD, Schnitzer B, Bakshi N, Janssen D, Klapper W, et al. ALK-positive diffuse large B-cell lymphoma with ALK-Clathrin fusion belongs to the spectrum of pediatric lymphomas. *Leukemia*. 2005;19:1839-40.
- [23] Stachurski D, Miron PM, Al-Homsi S, Hutchinson L, Harris NL, Woda B, et al. Anaplastic lymphoma kinase-positive diffuse large B-cell lymphoma with a complex karyotype and cryptic 3' ALK gene insertion to chromosome 4 q22-24. *Hum Pathol*. 2007;38:940-45.
- [24] Valera A, Colomo L, Martínez A, de Jong D, Balagué O, Matheu G, et al. ALK-positive large B-cell lymphomas express a terminal B-cell differentiation program and activated STAT3 but lack MYC rearrangements. *Mod Pathol*. 2013;26:1329-37.
- [25] Chikatsu N, Kojima H, Suzukawa K, Shinagawa A, Nagasawa T, Ozawa H, et al. ALK+, CD30-, CD20- large B-cell lymphoma containing anaplastic lymphoma kinase (ALK) fused to clathrin heavy chain gene (CLTC). *Mod Pathol*. 2003;16:828-32.
- [26] Jiang XN, Yu BH, Wang WG, Zhou XY, Li XQ. Anaplastic lymphoma kinase-positive large B-cell lymphoma: Clinico-pathological study of 17 cases with review of literature. *PLoS One*. 2017;12:e0178416.
- [27] Khanlari M, Jeffrey Medeiros L. ALK+large B-cell lymphoma with aberrant expression of CD3. *Blood*. 2020;136:3086.
- [28] Sandoval-Sus JD, Brahim A, Khan A, Deutsch Y, Raphael B, Ansari-Lari A, et al. Complete response of primary refractory ALK-positive large B-cell lymphoma treated with single-agent nivolumab. *Clin Lymphoma Myeloma Leuk*. 2020;20:e113-17.
- [29] Scott BJ, Douglas VC, Tihan T, Rubenstein JL, Josephson SA. A systematic approach to the diagnosis of suspected central nervous system lymphoma. *JAMA Neurol*. 2013;70:311-19.
- [30] de Borja MT, Chow E, Bovett G, Davis L, Gillies C. The correlation among patients and health care professionals in assessing functional status using the karnofsky and eastern cooperative oncology group performance status scales. *Support Cancer Ther*. 2004;2:59-63.
- [31] Hess LM, Brnabic A, Mason O, Lee P, Barker S. Relationship between progression-free survival and overall survival in randomized clinical trials of targeted and biologic agents in oncology. *J Cancer*. 2019;10:3717-27.
- [32] Dabbs DJ. Diagnostic immunohistochemistry: theranostic and genomic applications. 4th ed. Philadelphia: Elsevier Saunders; 2014.
- [33] Colomo L, Loong F, Rives S, Pittaluga S, Martínez A, López-Guillermo A, et al. Diffuse large B-cell lymphomas with plasmablastic differentiation represent a heterogeneous group of disease entities. *Am J SurgPathol*. 2004;28:736-47.
- [34] Sukswai N, Lyapichev K, Khoury JD, Medeiros LJ. Diffuse large B-cell lymphoma variants: an update. *Pathology*. 2020;52:53-67.
- [35] Hashimoto T, Fujimoto M, Nishikori M, Takeuchi K, Kimura M, Nakajima N, et al. Plasmacytic ALK-positive large B-cell lymphoma: A potential mimic of extramedullary plasmacytoma. *Pathol Int*. 2014;64:292-94.

PARTICULARS OF CONTRIBUTORS:

1. Associate Professor, Department of Pathology, Regional Cancer Centre, Thiruvananthapuram, Kerala, India.
2. Director, Department of Pathology, Regional Cancer Centre, Thiruvananthapuram, Kerala, India.
3. Associate Professor, Department of Pathology, Regional Cancer Centre, Thiruvananthapuram, Kerala, India.
4. Assistant Professor, Department of Pathology, Regional Cancer Centre, Thiruvananthapuram, Kerala, India.
5. Additional Professor, Department of Medical Oncology, Regional Cancer Centre, Thiruvananthapuram, Kerala, India.
6. Professor and Head, Department of Cancer Epidemiology and Biostatistics, Regional Cancer Centre, Thiruvananthapuram, Kerala, India.

NAME, ADDRESS, E-MAIL ID OF THE CORRESPONDING AUTHOR:

Dr. Jayasudha Arundhathi Vasudevan,
Associate Professor, Department of Pathology, Regional Cancer Centre,
Thiruvananthapuram-695011, Kerala, India.
E-mail: drjayasiv@gmail.com

AUTHOR DECLARATION:

- Financial or Other Competing Interests: None
- Was Ethics Committee Approval obtained for this study? Yes
- Was informed consent obtained from the subjects involved in the study? Yes
- For any images presented appropriate consent has been obtained from the subjects. NA

PLAGIARISM CHECKING METHODS: [Jain H et al.]

- Plagiarism X-checker: Jan 05, 2023
- Manual Googling: Feb 09, 2023
- iThenticate Software: Apr 18, 2023 (8%)

ETYMOLOGY: Author Origin

EMENDATIONS: 8

Date of Submission: **Jan 03, 2023**

Date of Peer Review: **Feb 17, 2023**

Date of Acceptance: **Apr 21, 2023**

Date of Publishing: **Jun 01, 2023**