



# Open Enucleation of the Talus in a Case Report

**Rajaallah A. <sup>a</sup>, Tabbak K. <sup>a\*</sup>, Jebbouri K. <sup>a</sup>, Lamnaouar F. <sup>a</sup>, Kassimi C. <sup>a</sup>, Rafaoui A. <sup>a</sup> and Rafai M. <sup>a</sup>**

<sup>a</sup> *Traumatology and Orthopedics Emergency Department, CHU Ibn Road of Casablanca, Morocco.*

## **Authors' contributions**

*This work was carried out in collaboration among all authors. All authors read and approved the final manuscript.*

## **Article Information**

### **Open Peer Review History:**

This journal follows the Advanced Open Peer Review policy. Identity of the Reviewers, Editor(s) and additional Reviewers, peer review comments, different versions of the manuscript, comments of the editors, etc are available here: <https://www.sdiarticle5.com/review-history/110974>

**Case Report**

**Received: 23/10/2023**

**Accepted: 29/12/2023**

**Published: 29/12/2023**

## **ABSTRACT**

We report a case of open enucleation of the talus, surgically treated conservatively. Enucleation or triple dislocation of the talus is a rare and serious traumatic injury. The study reports case of a 55 years old, was the victim of an attack by a stone with a direct point of impact on the right ankle while the foot was fixed, resulting in total functional impotence and severe pain. Enucleation of the talus is a rare lesion, rarely described in the literature. The functional prognosis of the ankle is compromised by the risk of osteonecrosis.

**Keywords:** *Enucleation of the talus; severe pain; osteonecrosis; traumatic injury.*

## **1. INTRODUCTION**

Talus Enucleation or triple dislocation of the talus is a rare traumatic injury [1,2] accounting for 2-10% of talar traumas [3,4]. A review of the literature revealed fewer than 80 cases of pure

enucleation of the talus [5], and the majority were a consequence of an open injury [3].

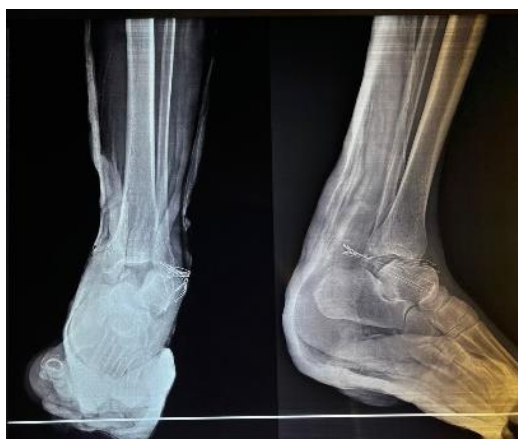The main risk factor for this type of injury is infection, which can even lead to osteonecrosis.

\*Corresponding author: E-mail: [tabb1993ak@gmail.com](mailto:tabb1993ak@gmail.com);

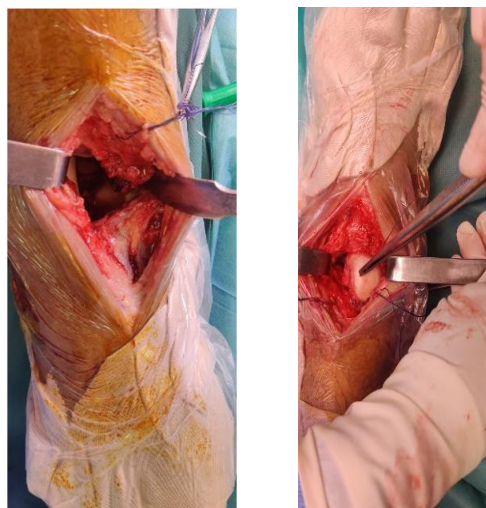
We report a case in which the patient underwent open enucleation of the talus and was surgically treated conservatively.

## 2. OBSERVATION

H. At 55 years of age, the victim of an attack by a stone, had a direct point of impact on the right ankle while the foot was fixed, resulting in total functional impotence and severe pain. Clinical examination revealed a varus deformity of the foot, with the talus protruding anteriorly and medially, associated with a 4 cm anteromedial wound classified as type II according to Cauchoix and Duparc, with no downstream vascular-nervous disorders. X-rays of the right ankle showed complete anterolateral enucleation of the talus without fracture of the malleolar pincer (Fig. 1).

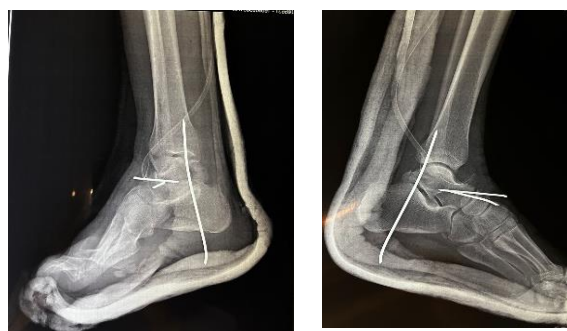

**Fig. 1. X-ray of the right ankle showing pure anterolateral talus dislocation**



**Fig. 2. Intraoperative aspect of talus enucleation**

Surgery was performed as needed. After the wound was trimmed, exploration revealed soft tissue incarceration, preventing reduction of the talus (Fig. 2). The soft tissue was therefore released, followed by reduction of the talus maintained by a trans-calcaneo-talo-tibial pin and two scapho-talar pins. The reduction was stable and maintained by a cast boot for two months (Fig. 3), followed by rehabilitation. The functional result was satisfactory at the last follow-up, with no signs of radiological necrosis.



**Fig. 3. Postoperative radiographic control**

## 3. DISCUSSION

The talus is exposed to significant traumatic risk due to the intermediate position between the leg and the foot and the absence of muscular or tendinous insertion. It is subjected to considerable stress during walking and other activities and is at the center of a highly mobile joint complex.

Talus Enucleation isn't an usually lesion that has rarely been described in the literature. The functional prognosis of the ankle is compromised by the risk of osteonecrosis. The direction of enucleation can var. most often is dislocated anterolaterally but the displacement may also be anteromedial or, and less in posteromedial.

However, the pathophysiological mechanism is still debated. For Pennal [6], anterolateral enucleation is performed through a dual process of forced plantar flexion and inversion. Plantar flexion results in rupture of the collateral ligament, while inversion leads to a tear of the talocalcaneal ligaments. The most precise study of enucleation mechanisms is that of Leitner (in 2), who described enucleation as the ultimate stage of supination trauma—in other words, the ultimate stage of medial subtalar dislocation. The

treatment advocated by the various authors is far from unequivocal. Currently, the trend goes for a conservative treatment for acute enucleations [2], reserving arthrodesis for secondary septic complications and late arthrosclerosis. The reduction of talus dislocation should be an emergency in order to prevent skin and vascular complications [7]. Tibiocalcaneal arthrodesis was adopted by Detenbeck and Kelly [3] but is a source of significant stiffness. Butel and Witvoet [9] noted the poor functional results of talectomy in enucleations of the talus and recommended triple arthrodesis as the first-line procedure, using the talus as a graft. Some authors recommend closed reduction with the aid of transcalcaneal traction [7].

Tibiocalcaneal arthrodesis was adopted by Detenbeck and Kelly [3] but is a source of significant stiffness. Butel and Witvoet [8] noted the poor functional results of talectomy in enucleations of the talus and recommended triple arthrodesis as a first-line treatment, using the talus as a graft. Some authors recommend closed reduction with the aid of transcalcaneal traction [7]. In the event of failure, the bloody approach is recommended [9,10]. Once the talus has been reduced, open focus allows the capsuloligamentous structures to be repaired [7,11]. Immobilization is achieved with a cast for four to eight weeks [7] or with a pin [11]. The evolution of talus enucleation is fraught with complications the main one being osteonecrosis after conservative treatment. Some authors consider this necrosis inevitable [2,9]. This is thought to be due to destruction of the capsuloligamentous attachments and complete rupture of the entire vascular supply [2]. As a few cases of enucleation of the talus have escaped this type of complication, several hypotheses can be put forward. Shahparee [2] suggested that the persistence of some ligamentous attachments, particularly the deltoid ligament, explains the inconsistency of necrosis. The tarsal canal artery is a branch of the posterior tibial artery and constitutes the main vascularization site of the body of the talus [13]. Its integrity at the time of the accident could explain the absence of talus necrosis in some anterolateral enucleations. Biga and Defives [1] reported a case of pure anterolateral enucleation of the talus treated by simple reduction.

At the two-year follow-up, we found no radiological signs of talar necrosis in any of our patients.

#### 4. CONCLUSION

Conservative treatment with reduction by external manoeuvring of an enucleation of the talus, whatever its variety, constitutes a major prognostic element to avoid damage by bloody reduction, which remains the vascular attachments and favors evolution toward osteonecrosis of the talus, which remains the main complication in this rare pathology.

#### ETHICAL APPROVAL

As per international standard or university standards written ethical approval has been collected and preserved by the author(s).

#### CONSENT

As per international standards or university standards, patient(s) written consent has been collected and preserved by the author(s).

#### COMPETING INTERESTS

Authors have declared that no competing interests exist.

#### REFERENCES

1. Biga N, Defives T. Adult malleolar fractures and instep dislocation. *encycl med chir. Musculoskeletal System*, Elsevier, Paris. 1997;14:088-10.
2. Asselineau A, Augereau B, Bombart M, et al. Partial or total enucleations of the astragalus. *interest in conservative treatment. Rev Chir Orthop* .1989;75:34-9.
3. Detenbeck LC, Kelly PJ Total dislocation of the talus. *J Bone Joint Surg (Am)* 1969;51:283-8.
4. Kenwright J, Taylor RG Major injuries of the Talus. *J Bone Joint Surg (Br)*. 1970;52:3-48.
5. Maffulli N, Francobandiera C, Lepore L. Total dislocation of the talus. *Foot Surg*. 1989;28:208-12.
6. Butel J, Witvoet J Fractures and dislocations of the talus. *Rev Chir Orthop* 1967;53:494-624.
7. Pinzur MS, Meyer PR Complete posterior dislocation of the talus. *Case report and discussion. Clin Orthop*. 1978;231:205-9.
8. Mann RA Total dislocation of the talus: *Surgery of the foot (5th ed.)*. In: Mann RA, Mosby CV (ed.), St Louis. 1986;770-3.
9. Ritsema GH Total talus dislocation. *J Trauma*. 1988;28:692-4.

10. Korovessis P, Sidiropoulos P, Katsardis T, et al. Complete lateral dislocation of the talus without fracture. Orthop Trauma. 1992;6:125-8.
11. Shahraree H, Sajadiik AK, Silver C, et al. Total dislocation of the talus, a case report four-year follow-up. Ortho Rev. 1980;9: 65-8.
12. Hidalgo Ovejero AM et al. Posterior medial dislocation of the talus. A case report and review of the literature Acta Othop Belg ; 1991.
13. Curvale G Traumatic pathology of the talus. SOFCOT teaching notebooks. Teaching conferences, Paris. 1999: 87-102.

© 2023 Rajaallah et al.; This is an Open Access article distributed under the terms of the Creative Commons Attribution License (<http://creativecommons.org/licenses/by/4.0>), which permits unrestricted use, distribution, and reproduction in any medium, provided the original work is properly cited.

*Peer-review history:*

*The peer review history for this paper can be accessed here:*  
<https://www.sdiarticle5.com/review-history/110974>