



Chronic Oral Administration of *Ocimum gratissimum* Leaf Extract Induced Gastrointestinal Necrosis in Treated Albino Rats

M. U. Udoha^{1,2*}, N. J. Okolie¹ and S. N. Ijioma³

¹*Department of Medical Laboratory Science, Faculty of Health Sciences, Imo State University, Owerri, Imo State, Nigeria.*

²*Department of Medical Laboratory Services, Federal Medical Center, Umuahia, Abia State, Nigeria.*

³*Department of Veterinary Physiology and Pharmacology, College of Veterinary Medicine, Michael Okpara University of Agriculture, Umudike, Abia State, Nigeria.*

Authors' contributions

This work was carried out in collaboration among all authors. All authors read and approved the final manuscript.

Article Information

DOI: 10.9734/EJMP/2019/v27i330113

Editor(s):

- (1) Dr. Gaurav Kumar, Center for Cancer Prevention and Drug Development (CCPDD), Dept. of Medicine, University of Oklahoma Health Sciences Center (OUHSC), Oklahoma, USA.
(2) Dr. Paola Angelini, Department of Applied Biology, University of Perugia, Italy.
(3) Dr. Marcello Iriti, Professor, Plant Biology and Pathology, Department of Agricultural and Environmental Sciences, Milan State University, Italy.

Reviewers:

- (1) Isaac O. Adejumo, Landmark University, Nigeria.
(2) Adalberto Alves Pereira Filho, Universidade Federal de Minas Gerais, Brazil.
Complete Peer review History: <http://www.sdiarticle3.com/review-history/23749>

Original Research Article

Received 21 August 2016
Accepted 02 November 2016
Published 05 April 2019

ABSTRACT

Aim: This study was designed to investigate the effect on of *Ocimum gratissimum* leaves extract on the histology of the gastrointestinal tract in rats.

Study Design: Adult rats of both sexes were used for the work. The study was carried out at the Departments of Physiology and Histology, College of Veterinary Medicine, Michael Okpara University of Agriculture, Umudike, Nigeria between September 2014 and January, 2015.

Methodology: Fifty adult albino rats and 35 Mice were used for the study. The mice were used for acute toxicity study while the rats were divided into five groups of 10 rats each and were used for the histological study. Groups 2-5 were assigned different dose levels of OGLE in the order 100, 200, 400 and 800 mg/kg respectively while group 1 was given only feed and water. Treatment was given by the oral route and lasted for 28 days.

*Corresponding author: E-mail: mudoha2014@gmail.com;

Results: Phytochemical compounds identified in the extract include protein and carbohydrate which occurred in high amounts, tannins, flavonoids and glycosides in moderate quantities, saponins, steroids and phenolic compounds in low amounts while tannins and alkaloids were absent. An LD₅₀ and ED₅₀ values of 2075 mg/kg and 850 mg/kg body weight respectively were obtained for the extract with a Therapeutic Index value of 2.44. Chronic oral administration of the extract also caused various degrees of histological changes in the gastrointestinal tract in all treated animals with significant erosions of the mucosa and submucosa. The gastrointestinal necrosis produced by *Ocimum gratissimum* leaf extract after long term treatment was dose dependent with 100 mg/kg inducing only mild necrosis of the villi, 200 mg/kg, a higher necrosis of the villi, while 400 mg/kg and 800 mg/kg induced severe necrosis of both the villi and the intestinal mucosa.

Conclusion: Results obtained from this study therefore suggest that *Ocimum gratissimum leaf extract* is rich in bioactive compounds and may be well tolerated at low to moderate doses during short term treatment but may cause gastrointestinal erosions when used continuously over a long period.

Keywords: Erosions; necrosis; gastrointestinal mucosa; *Ocimum gratissimum*; rats.

1. INTRODUCTION

Ocimum gratissimum also known as African Basil is a plant belonging to the order *Lamiales*, and family *Lamiaceae*, Genus: In Nigeria it is commonly called, Ncho-anwu or Ahuji (Igbo), Efinrin (Yoruba), Aramogbo (Edo) and Daidoya (Hausa) [1]. *Ocimum gratissimum* is an aromatic, perennial herb, 1-3 m tall; stem erect, round-quadrangular, much branched, glabrous or pubescent, woody at the base, often with epidermis peeling in strips [2]. The plant is indigenous to tropical areas, including India and West Africa. In Nigeria, It is found in the Savannah and coastal areas [3]. Its characteristic pleasant aroma is attributed to its volatile oil content [4]. The plant is well known in Nigeria folk medicine and has been used to manage various disease conditions, including rheumatism, paralysis, epilepsy, diarrhea, influenza and gonorrhoea [5,6]. Leaves of the plant are used as a spice and condiment in the southern part of Nigeria to facilitate removal of blood clots from the female reproductive system after delivery [7]. Antidiarrheal effects [8], gastro-protective properties [9], anti-bacterial activity [10], anti-fungal properties [11], anti-mutagenic activity [12], have all been reported to be among the health benefits of *Ocimum gratissimum*. Treatment of skin diseases, pneumonia, tooth and gum disorder, fever, and as mosquito repellants have also been reported [13].

The fact that the majority of African biomes are host to numerous plants of medicinal values makes herbal medicine a practice of choice for a larger population of the inhabitants. It has indeed been reported that over 80% of the world's

population, particularly in the developing countries is relying on herbal remedies for the treatment of various endemic health problems [14]. This of course may be for reasons of cost, availability, accessibility, culture and effectiveness. Research scientists have of late formed an alliance with traditional herbal practitioners as a means of getting first hand information on the medicinal uses of these plants for the purpose of verifying such claims scientifically. In most cases the validity of such claims usually leads to the development of new and pure substances for the treatments of diseases [15]. Thus the interest in herbal medicine is in no way surprising. Of much concern however is the manner in which these herbal preparations are taken without proper information on their possible deleterious effects. It is established that most plants are rich in numerous phytochemicals [16], some of which may produce systemic toxicity when introduced into the body at concentrations beyond tolerable limits. Several plants are currently being studied



Fig. 1. *Ocimumgratissimum* plants source (www.onlyfoods.net/ocimum-gratissimum.html)

for toxicity effects and *Ocimum gratissimum* is one of them. This study is therefore aimed at assessing the effect of chronic administration of *Ocimum gratissimum* leaf extract on the gastrointestinal tract. The findings from the study could provide the needed information on safe use of the extract and could also serve as a reference for further studies.

2. MATERIALS AND METHODS

2.1 Collection of Plant Material

Fresh leaves of *Ocimum gratissimum* were collected from a local settlement in Umuahia South Local Government Area of Abia State, Nigeria. The leaves were authenticated as *Ocimum gratissimum* leaves by a Botanist in the Department of Plant Science and Biotechnology, College of Natural Sciences, Micheal Okpara University of Agriculture, Umudike Abia State. A voucher number 15/MOUAU/CVM/026 was given and a sample was deposited at the Departmental herbarium.

2.2 Preparation Leaf Extract

The collected fresh leaves of *Ocimum gratissimum* were dried under shade for ten days, after which they were milled to fine powder using a manual blender (Corona, 4D071003, Landers Co.). Fifty (50) grams of the powdered sample was introduced into the extraction chamber of the soxhlet extractor and extraction was done using ethanol as solvent. Temperature was maintained at 70°C throughout the extraction period of 48 hours. At the end of the period, the extract was dried in a laboratory oven at 40°C to obtain dried dark green oily extract which weighed 11.25 g and represented a yield of 22.50%. The extract was preserved at 4°C in a refrigerator until needed.

2.3 Animals

A total of 35 adult albino mice (30 to 40 g) and 50 rats (150 to 200 g) were used for this study. The mice were used for acute toxicity study while the rats were used for the histological study. The animals were obtained from the Animal Production Unit of the College of Veterinary Sciences, Michael Okpara University of Agriculture Umudike and were housed in aluminum cages and allowed to acclimatize for one week for proper adaptation to the new environment and living conditions. They were fed at liberty with standard feed and clean water but

starved for 12 hours prior to the commencement of the experiment. All animal experiments were conducted in compliance with NIH guidelines for care and use of laboratory animal (Pub.No 58-23, Revised 1985) as reported by [17]. This work was carried out at the Physiology Laboratory of the Department of Veterinary Physiology, Michael Okpara University of Agriculture, Umudike, Abia State, Nigeria.

2.4 Phytochemical Composition of *Ocimum gratissimum* Leaves Extract

Phytochemical scening of the extract was carried out using the methods of Trease and Evans [18], Harborne [19] and Sofowora [8] as reported by Deka and Kalita [20].

* **Test for Proteins:** Few drops of nitric acid were added by the sides of a test tube very gently to 1 ml of the extract. Formation of yellow colouration indicated the presence of protein.

* **Test for Carbohydrate:** 1 ml each of Fehling A and Fehling B were added to a diluted portion of the extract and heated for 30 minutes and observed for the formation of brick red colouration which would indicate the presence of carbohydrate.

* **Test for Resins:** 5 ml of distilled water was added to a little amount of the extract in a test tube and observed for turbidity which would indicate the presence of resins.

* **Test for Tannins:** 5 ml of 45% ethanol was added to 2 g of extract and boiled for 5 minutes. The mixture was then cooled and filtered. 3 drops of lead sub acetate solution was added to 1 ml of the filtrate. A gelatinous precipitate observed indicated the presence of tannins. Another 1 ml of the filtrate was added to 0.5 ml of bromine water. A pale brown precipitate confirmed the presence of tannins.

***Test for Saponins:** 0.5 g of the extract was added to 5 ml of distilled water in a test tube. The solution was shaken vigorously and observed for a persistent froth. The frothing was mixed with 3 drops of olive oil and shaken vigorously. The formation of an emulsion indicated the presence of saponin.

* **Test for Flavonoids:** 0.5 g of the extract was introduced into 10 ml of ethyl acetate

and heated in boiling water for 1 minute and then filtered. 4 ml of the filtrate was shaken with 1 ml of 1% aluminum chloride solution and allowed to stand. The formation of a yellow colour after addition of 1 ml dilute ammonia solution indicated the presence of flavonoids.

* **Test for Alkaloids:** 5 g of dry powdered *Ocimum gratissimum* leaves was extracted with 10 ml of Ammonical chloroform and 5 ml of chloroform. The mixture was filtered and the filtrate was shaken with 10 drops of 0.5M H₂SO₄. The observation of creamish white precipitate would indicate the presence of alkaloids.

* **Test for Steroids:** 2 ml of acetic anhydride was added to 0.5 g of the extract and 2 ml of sulphuric acid was added by the sides of the test tube. A violet or blue-green colouration indicated the presence of steroids.

* **Test for Phenolic compounds:** a little quantity of the extract was mixed with distilled water in a test tube and was warmed. 2 ml of Ferric chloride solution was then added. The formation of a green or blue colour indicated the presence of phenolic compounds.

* **Test for Glycosides:** About 0.5 ml of the extract was added to 1 ml of glacial acetic acid containing traces of Ferric chloride in a test tube. To this solution 1 ml of concentrated Sulphuric acid was added and observed for the formation of reddish brown colouration at the junction of the two layers with the upper layer turning bluish green. This indicated the presence of glycosides.

2.5 Acute Toxicity Studies (LD₅₀ Determination)

For acute toxicity study, 35 mice of both sexes weighing 30-40 g were divided into 7 groups of 5 mice each. Each group was assigned a particular oral dose level of *Ocimum gratissimum* leaves extract such that groups 1, 2, 3, 4, 5, 6 and 7 were administered 500, 750, 1000, 1500, 2000, 2500, and 3000 mg/kg body weight respectively. After the administrations the mice were returned to their cages and allowed free access to feed and water and were observed for toxicity signs and number of deaths within a period of 24 hours. The LD₅₀ value for the extract was

determined using the arithmetic method of Kerbar as reported by Enegeide et al. [21].

2.6 Histological Changes Following Chronic Oral Administration of *Ocimum gratissimum* Leaf Extract on the Intestine

Fifty (50) rats of both sexes weighing 150-200 g were divided into 5 groups of 10 rats each and were assigned *Ocimum gratissimum* treatments as stated below:

- Group 1: Treated with 5 ml/kg body weight of normal saline and served as the control group.
- Group 2: Treated with 100 mg/kg body weight of *Ocimum gratissimum* leaf extract.
- Group 3: Treated with 200 mg/kg body weight of *Ocimum gratissimum* leaf extract.
- Group 4: Treated with 400 mg/kg body weight *Ocimum gratissimum* leaf extract.
- Group 5: Treated with 800 mg/kg body weight *Ocimum gratissimum* leaf extract.

Treatments were given via the oral route by gavage and lasted for 28 days. At the end of the treatment period, animals in all groups were sacrificed after chloroform anesthesia and the small intestines were harvested into specimen bottles containing 10% formal saline and preserved for histological studies. The tissues were prepared for histological examination following the methods of John and Alan [22] and Clayden [23]. In these techniques, slices of the intestinal tissue were fixed in 10% formal saline for 48 hours after which they were processed by placing them in ascending grades of alcohol in the order, 50% alcohol for 1 hour, 70% alcohol for 1 hour, first 95% alcohol for 1 hour and second 95% alcohol for 1 hour 15 minutes, first absolute alcohol for 1.5 hours and second absolute alcohol for 2 hours to properly dehydrate the tissues. The dehydrated tissues were then transferred to a mixture of equal volumes of alcohol and xylene where they were left overnight and later cleared with two changes of xylene for 1 hour each. They were then infiltrated twice for 1 hour each with molten paraffin wax in the oven at 60°C and then embedded in paraffin wax, trimmed and mounted on a wooden chuck for sectioning at 5µm thickness in a microtome. The sections were floated in floating-out bath from where they were picked with clean albuminized slides and were placed in a staining dish. Excess wax was removed by two changes of xylene and hydrated

by descending grades of alcohol in the order- absolute alcohol, 95% alcohol and 70% alcohol for 2 minutes each. The slides were then stained by infiltrated Ehrlich haematoxylin for 15 minutes, and then washed in water for 5 minutes, differentiated in 10% acid alcohol and blued in running tap for 10 minutes. They were then counter stained with filtered eosin for 2 minutes. Excess eosin was removed in ascending grades of alcohol in the order- 75% alcohol, 95% alcohol and absolute alcohol for 2 minutes each. They were then cleared in two changes of xylene and each was cover slipped with depex mountant (Clayden, 1967; John and Alan, 1977). The slides were viewed under a light microscope and selected images were captured using a moticom 2.0 digital camera attached to a computer.

2.7 Statistical Analysis

Results were expressed as Means± standard error of mean (SEM) and analyzed using one way Analysis of variance via computer software IBM SPSS statistics for windows version 20.0, New York. P-values less than 0.05 at 95% level of significance were considered significant.

3. RESULTS

3.1 Phytochemical Composition of *Ocimum gratissimum* Leaves Extract

Results of phytochemical analysis revealed the presence of protein and carbohydrate which in high amounts, tannins, flavonoids and glycosides in moderate quantities, saponins, steroids and phenolic compounds in low amounts while tannins and alkaloids were absent (Table 1).

3.2 Acute Toxicity (LD₅₀) Study and Effective Dose (ED₅₀) Values

Toxicity signs and deaths were observed in some groups during the acute toxicity study period. No death was recorded in groups 1 and 2 treated

with 500 and 750 mg/kg, but groups 3 to 7 treated with 1000, 1500, 2000, 2500 and 3000 mg/kg body weights recorded 1, 1, 2, 3 and 5 deaths respectively in addition to obvious signs of toxicity (Table 1).

LD₅₀ value by Karber's arithmetic method was thus obtained:

$$LD_{50} = LD_{100} - \frac{\sum(DD \times DM)}{N}$$

$$3000 - \frac{4625}{5}$$

$$3000 - 925 = 2075\text{mg/kg}$$

Table 1. Phytochemical composition of *Ocimum gratissimum* leaves extract

Phytochemical substance	Inference
Protein	+++
Carbohydrate	+++
Resins	---
Tannins	++
Saponins	+
Flavonoids	++
Alkaloids	---
Steroids	+
Phenolic compounds	+
Glycosides	++

+++ indicates high, ++ indicates moderate, + indicates low, --- indicates absent

3.3 Effect of *Ocimum gratissimum* Leaf Extract on Gastrointestinal Tissue Histology

The results of the intestinal histopathology showed that all rats treated with *Ocimum gratissimum* leaf extract for the 28 days period had a dose dependent intestinal mucosal lesions and erosions when compared to the control animals. However, the villi, intestinal glands, sub-mucosa and muscle layers were essentially intact in the control animals (Plate 1), the villi and a portion of the intestinal glands were eroded in all treatment groups (Plates 2-5).

Table 2. LD₅₀ Mortality effects of ethanol leaf extract of *Ocimum gratissimum*

Group	Dose	No of deaths	Percentage mortality	Dose difference (Dd)	Mean death (Md)	Dd x Md
1	500	0	0	250	0	0
2	750	0	0	250	0.5	125
3	1000	1	20	500	1.0	500
4	1500	1	20	500	1.5	750
5	2000	2	40	500	2.5	1250
6	2500	3	60	500	4.0	2000
7	3000	5	100			

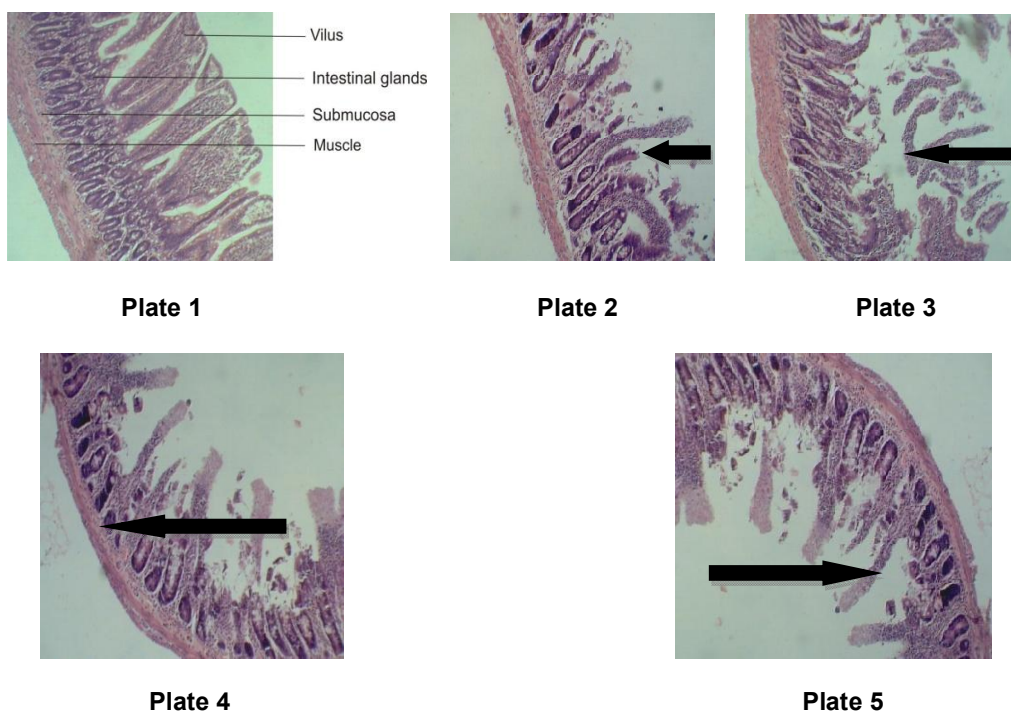


Plate 1. Photomicrograph of a histological section of the gastrointestinal tract of a normal rat Haematoxylin and Eosin x 10

Plate 2. Photomicrograph of a histological section of the gastrointestinal tract of rat treated with 100 mg/kg *Ocimum gratissimum* leaf extract, Haematoxylin and Eosin x 10 showing mild necrosis of the villi

Plate 3. Photomicrograph of a histological section of the gastrointestinal tract of rat treated with 200 mg/kg *Ocimum gratissimum* leaf extract, Haematoxylin and Eosin x 10 showing severe necrosis of the villi

Plate 4. Photomicrograph of a histological section of the gastrointestinal tract of rat treated with 400 mg/kg *Ocimum gratissimum* leaf extract, Haematoxylin and Eosin x 10 showing necrosis of the villi and intestinal gland

Plate 5. Photomicrograph of a histological section of the gastrointestinal tract of rat treated with 800 mg/kg *Ocimum gratissimum* leaf extract. Haematoxylin and Eosin x 10 showing necrosis of the villi and intestinal gland

4. DISCUSSION

The high percentage yield obtained after the soxhlet extraction of *Ocimum gratissimum* leaves suggests that the plant is heavily enriched with bioactive substances which can be harnessed into useful forms to help surmount the numerous health challenges of man and other animals. The presence of these bioactive substances may be why *Ocimum gratissimum* leaves have been used over the years for the management of diseases [24] and may be the cause of observed responses in this current work. Similar result was obtained after subjecting the leaves of *Ocimum gratissimum* to soxhlet extraction using ethanol as solvent as reported [7].

The LD₅₀ result indicates that *Ocimum gratissimum* leaf extract have low toxicity and could be well tolerated at low to moderate doses which accounts for its use in most part of the world for the management of diseases. This result agree with [25], who reported that animals administered *Ocimum gratissimum* showed no overt sign of distress or toxicity even at a dose of 800 mg/kg body weight. However the toxicity signs revealed by the gastrointestinal histology may be due to long time exposure of the intestinal mucosa to the extract. The rats that died during the acute toxicity (LD₅₀) tests may have received toxic doses of *Ocimum gratissimum* leaf extract. Results of phytochemical analysis had revealed the presence of protein, carbohydrate, tannins,

flavonoids, glycosides, saponins, steroids and phenolic compounds in various amounts, some of which have been implicated in various forms of systemic toxicity due to their presence in various herbal preparations [26]. Cytotoxicity have also been reported in association with the use of some these phytochemical agents [27]. The American Chemical Society also had stated that liver, kidney and intestinal toxicities are associated with consumption of high doses of plant phytochemicals- particularly phenolic compounds [28]. The acute toxicity result however indicates that *Ocimum gratissimum* leaf extract is only toxic at high doses. An LD₅₀ value of 2075 mg/kg, ED₅₀ value of 850mg/kg and therapeutic index of 2.44 suggest a significant margin of safety since more than twice of the effective dose is required to produce mortality. OECD guidelines on acute oral toxicity test [29], had reported that non observation of mortality within an animal population treated with a dose range at which mortality is expected indicates tolerance or lack of acute toxicity. This is because mortality is the expected end point of acute oral toxicity test [29]. *Ocimum gratissimum* was therefore well tolerated at low doses but could be toxic at higher doses and long term treatment, even at moderate doses. The toxicity produced by *Ocimum gratissimum* was dose dependent, having some low doses that would kill no animal, some high doses that will be uniformly lethal and an intermediate dose range in which a varying fraction of the population will be killed which may be due to the presence of saponins, cyanogenetic glycosides and tannins [9], which were found to be part of its phytochemistry. These compounds have been reported to have high possibility of causing toxicity at high doses [14]. It has however been reported that an extrapolation of acute toxicity doses from experimental animals to man is hardly possible [30], as it may be difficult for any human to consume such concentration at any given time. For instance, the acute toxicity value is 2075 mg/kg, but when extrapolated to a man of body weight 60kg it becomes 124500 mg (124.5 g) worth of extract which no man can ever consume at a time. This may explain the reason for the safety associated to the use of *Ocimum gratissimum* over the years [31].

The gastrointestinal toxicity associated with long term use of *Ocimum gratissimum* may be the reason for the intestinal mucosal erosions, inflammatory reactions and necrosis which were seen as obvious signs of intestinal toxicity arising from long term exposure to the extract as

observed in all rats treated with the extract (Plates 2 to 5). Orafidiya et al. [11] had reported changes in intestine weights of rats treated with *Ocimum gratissimum* leaf extract during an acute and subchronic toxicity studies. Consumption of phenolic compounds in high doses has also been reported to be a major cause of intestinal toxicity [25]. Histopathological effects resulting from the activity of *Ocimum gratissimum* leaf extract on bowel movement, intestinal discharge and the mucosa have also been reported [1] and agree with the findings of this study.

5. CONCLUSION

The ethanol leaf extract of *Ocimum gratissimum* was found to be tolerated in treated animals at low and moderate doses but with evidence of toxicity at high doses and long term treatment even at moderate doses, hence the need for carefully controlled usage of the extract in the management of diseases.

CONSENT

It is not applicable.

ETHICAL APPROVAL

The authors declare that this work was not carried out against public interest and that animal experiment was conducted in accordance animal ethics guidelines as prescribed by NIH.

COMPETING INTERESTS

Authors have declared that no competing interests exist.

REFERENCES

1. Efrain IO, Salami HA, Osewa TS. The effect of aqueous leaf extract of *Ocimum gratissimum* on haematological and biochemical parameters in rabbits. *Afri. J. Biomed Res.* 2000;175–179.
2. Orwa CA, Mutua KR, Jamnadass RSA. *Agroforestry database. A Tree Reference and Selection Guide Version, 4.0*; 2009.
3. Nogoichi NE. Phenolic antioxidants; a rationale for design and evaluation of novel antioxidant drugs for arteriosclerosis. *Free Rad. Biol. Med.* 2000;28:1538-1546.
4. Prabhu KS, Lobo AA, Shirwaikar AA, Shirwaikar A. *Ocimum gratissimum*: A review of its chemical, pharmacological

- and ethnomedicinal properties. The Open Complementary Medicine Journal. 2009;1: 1-15.
5. Dalziel JM. Plants description, useful plants of west tropical Africa. 1993;3:431-433.
 6. Dhawan BN, Patnik GR, Rastogy RAT, Singh KK, Tandol TS. Screening of Indian plants for biological activity. YL India Exp. 1997;15:108.
 7. Akomas SC, Ijioma SN. Bleeding clotting times effects of ethanolic extracts of *Chromolaena odorata* versus *Ocimum gratissimum* treated albino rats. Comprehensive Journal of Medical Sciences. 2014;2(1):9-13.
 8. Sofowora LA. Medicinal plants and traditional medicine Africa. Spectrum Books, Ltd, Ibadan. 1993;55-71.
 9. Offiah VN, Chukwuodu UA. Antidiarrhoeal effects of *Ocimum gratissimum* leaf extract in experimental animals. Ethnopharmacol. 1999;68(1-3):27-30.
 10. Akah PA, John-Africa L, Nworu CS. Gastro-protective properties of *Ocimum gratissimum* L. against experimental ulcers in rat. International Journal of Pharmacology. 2007;3:461-467.
 11. Orafidiya OO, Elujoba AA, Iwalewa FO, Okeke IN. Evaluation of antidiarrheal properties of *Ocimum gratissimum* volatile oil and its activity against enteroaggregative *Escherichia coli*. Pharm. Pharmacol. Lett. 2000;10:9-12.
 12. Njoku CJ, Asuzu IU. The anthelmintic effects of the leaf extract of *Ocimum gratissimum* (L.). Phytomedicine. 1998; 5(6):485-8.
 13. Ilori M, Sheteolu AO, Omonigbehin EA, Adeneye AA. Antibacterial activity of *Ocimum gratissimum* (Lamiaceae). J. Diarrhoeal Dis. Res. 1996;14:283-285.
 14. Nweze EI, Eze EE. Justification for the use of *Ocimum gratissimum* L in herbal medicine and its interaction with disc antibiotics. BMC Complementary and Alternative Medicine. 2009;9(37). Article Number 1472.
 15. Ojeh AE, Adegor EC, Lawrence EO. Preliminary phytochemical screening, analgesic and anti-inflammatory properties of *Celosia isertii*. European Journal of Medicinal Plants. 2013;3(2):369-380.
 16. Ijioma SN, Nwankudu ON, Nwankwo AA. Gastroprotective effects of *Loranthu smicranthus* and *Acalypha wilkesiana* leaves extracts on experimentally induced ulcer models in rats. International Journal of Current Research. 2015;7(04):14481-14485.
 17. Akah J, Alemji JA, Salawef OA, Okoye TC, Offiah NV. Effect of *Vernonia amygdalina* on biochemical and haematological parameters in diabetic rats. Asian Journal of Medical Science. 2009;1(3):108-113.
 18. Trease GE, Evans WC. Pharmacognosy, 11th Edition. Brailliar Tindel Can. Macmillian Publishers; 1989.
 19. Harborne E. Phytochemical methods. London. Chapman and Hall Ltd; 1973.
 20. Deka M, Kalita JC. Preliminary phytochemical analysis and acute oral toxicity study *Mucuna pruriens* Linn in albino mice. International Research Journal of Pharmacy. 2012;3(2):181-184.
 21. Enegide C, David A, Fidelis SA. A new method for determining acute toxicity in animals models. Toxicol International. 2003;20(3):224-226.
 22. John BW. Physiological basis of medical practice. 12th Edition. Williams and Wilkins Publishing Company London. 1990;371-383.
 23. Clayden EC. Practical section cutting and staining, 4th Edition. J and E Church Hill Ltd, UK. 1967;87.
 24. Olusegun RJ, Josiah O, Luqman AO, Ayokunle O, Sikiru AB. Effects of aqueous extract of *Ocimum gratissimum* on haematological parameters of Wistar rats. An International Journal of Nigerian Society for Experimental Biology. Biokemistri. 2008;20(1):33-37.
 25. Omobuwajor OR, Alade GO, Akanmu MA, Obuotor EM, Osasan SA. Microscopy and toxicity studies on the leaves of *Ocimum gratissimum*. African Journal of Pharmacy and Pharmacology. 2011;5(1):12-17.
 26. Naughton C. Drug-induced nephrotoxicity. A Publication of the American Academy of Family Physicians; 2008. Available:www.aafp.org/afp
 27. Horn RC, Vagas VF. Antimutagenic activity of extracts of natural substances in the Salmonella/microsome assay. Oxford Journals (Mutagenesis). 2002;18(2):113-118.
 28. American Chemical Society. High doses of phytochemicals including flavonoids in teas and supplements could be unhealthy; 2007. Science Daily. Available:www.sciencedaily.com

29. OECD. Guidelines for the testing of chemicals/section 4: Health effects tests no, 423: Acute oral toxicity – acute toxic class method. Organization for Economics Cooperation and Development; 2001. Paris
30. Auwal SM, Atiku MK, Wudil AM, Sule MS. Phytochemical composition and acute toxicity evaluation of aqueous root bark extract of *Securidaca longipedunculata*. Bayero Journal of Pure and Applied Sciences. 2006;5(2):67-72.
31. Iweala EEJ, Obidoa O. Studies on some biochemical and histological changes associated with long term consumption of leaves of *Ocimum gratissimum* in male rats. American Journal of Food Technology. 2010;5:376-384.

© 2019 Udoha et al.; This is an Open Access article distributed under the terms of the Creative Commons Attribution License (<http://creativecommons.org/licenses/by/4.0>), which permits unrestricted use, distribution, and reproduction in any medium, provided the original work is properly cited.

Peer-review history:
The peer review history for this paper can be accessed here:
<http://www.sdiarticle3.com/review-history/23749>