

Corneal Abscesses Profile and Management: A 5 Years Experience in a Tertiary Eye Care Center

R. Zerrouk^{1*}, Y. Bennouk², M. Khmamouche¹, A. Elkhoyaali¹, Y. Malek¹,
Y. Mouzari¹, F. Elasri¹, K. Reda¹ and A. Oubaz¹

¹Department of Ophthalmology, Mohamed V Military Training Hospital, University of Medicine and Pharmacy, Rabat, Morocco.

²Department of Ophthalmology, Military Hospital Avicenne, Marrakech, Morocco.

Authors' contributions

This work was carried out in collaboration among all authors. Author RZ contributed to the photography and writing of the article. Authors YB and MK contributed to the statistical analysis. Authors AE and Y. Malek managed the analyses of the study. Authors Y. Mouzari and FE contributed to the bibliographic research. Authors KR and AO approved the study. All authors read and approved the final manuscript.

Article Information

Editor(s):

(1) Dr. Archana Sunil Nikose, Associate Professor, Department of Ophthalmology, NKP Salve Institute of Medical Sciences and Research Center, India.

(2) Dr. Panagiotis Tsikripis, University of Athens, Greece.

Reviewers:

(1) Nélide Virginia Gómez, Buenos Aires University, Argentina.

(2) Tayo Julius Bogunjoko, Eye Foundation Hospital, Nigeria.

Complete Peer review History: <https://sdiarticle4.com/review-history/51845>

Original Research Article

Received 01 September 2019

Accepted 02 November 2019

Published 08 November 2019

ABSTRACT

Aims: To define the epidemiological, clinical, bacteriological, therapeutic and progressive characteristics of severe corneal abscesses treated in a tertiary eye care center.

Study Design: Retrospective Study.

Place and Duration of Study: The ophthalmology department of The Mohammed V Military Medical Training Hospital in Rabat, and covering patients with corneal abscesses from January 2014 to December 2018.

Results: We report 30 cases of severe corneal abscess. With a sex ratio of 1.2, average age of 42.20 years, ranging from 16 to 74 years. The average consultation time after the onset of the first symptoms was 6.6 days with extremes of 2 to 14 days. The initial visual acuity, at the time of hospitalization, was between 03/10 and absence of light perception. The diameter of the abscess was between 2 and 5 mm in 6 cases (20%) and greater than 5 mm in 24 cases (80%). For 4

*Corresponding author: E-mail: rachidzerrouk@outlook.com;

patients the light perception was negative before hospitalization. For 5 patients, the infection did not have much impact on function of which two patients recovered 10/10 and for 16 patients the acuity remained reduced (between positive light perception at 01/10). Eight patients were cold programmed for corneal transplantation. And 4 cases for evisceration.

Keywords: Corneal abscess; severe; epidemiology.

1. INTRODUCTION

Corneal abscesses are a group of serious conditions, it is one of the main causes of corneal blindness. The prevalence of this condition, about 0.148% is constantly increasing [1], due to the frequency of risk factors. Epidemiological and microbiological characteristics are variable. The main risk factors for corneal abscesses are eye trauma in developing countries and contact lens wear in industrialized countries [2] This serious pathology and reserved prognosis is formidable because of the difficulty of its etiological diagnosis and therapeutic management. The positive diagnosis is clinical. The etiological diagnosis is essentially microbiological, based on corneal samples [3] Therapeutic management must be early and oriented according to the etiological investigation and abscess appearance to avoid the occurrence of serious complications and permanent sequelae [4]. Corneal perforation and endophthalmitis are the most serious complications and visual acuity is often reduced by central corneal opacity [5]. The purpose of our study is to define the epidemiological, clinical, bacteriological, therapeutic and progressive characteristics of severe corneal abscesses treated in the ophthalmology department of the Mohamed V Military Training Hospital (HMIMV) in Rabat (Morocco).

2. MATERIALS AND METHODS

This is a retrospective study of a series of 30 eyes from 29 hospitalized patients in the ophthalmology department of the HMIMV in Rabat between January 2014 and December 2018. Our inclusion criteria were: an abscess diameter greater than 2 mm and a depth greater than 50% of the corneal thickness, a state of immunosuppression, poor treatment compliance, central location of the lesion, intraocular inflammation, pre-perforation and a fortiori perforation. The exclusion criteria were: Any non-severe abscess with a diameter less than 2 mm and a depth less than 50% of the corneal thickness.

The parameters studied were: age, sex, time of consultation after symptom onset, risk factors,

initial and subsequent visual acuity (evaluated by the Snellen scale), the microbiological results of the corneal samples taken, treatment introduced in the department and evolution. We also took into account the following clinical characteristics: the size of abscess, location (central, paracentral, peripheral), existence of a Endocular inflammation. For each abscess a corneal scraping was performed.

3. RESULTS

We have reported 30 cases of severe corneal abscess in 29 patients over a 5-year period.

The male-to-female ratio was 1.2 (16 men to 13 women). The average age was 42.20 years, ranging from 16 to 74 years.

The abscess was always unilateral (40% OD and 60% OS) except in one case.

The average consultation time after the onset of the first symptoms (redness of the eyes, pain and decreased visual acuity) was 6.6 days with extremes of 2 to 14 days.

Eight risk factors were objectively assessed in 27 patients, representing 93.1% of cases, including some with two risk factors at the same time (Table 1).

Clinical aspects: The initial visual acuity, at the time of hospitalization, was between 03/10 and absence of light perception. On initial examination, 27 abscesses were central (Fig. 1) and 3 were paracentral. There was no inflammatory reaction of the anterior chamber in 10 cases (33.3%) with hypopyon in 6 cases, and in 7 cases (23.3%) the anterior chamber was not examinable because of the large volume of the abscess. The diameter of the abscess was between 2 and 5 mm in 6 cases (20%) and greater than 5 mm in 24 cases (80%).

Microbiological characteristics: A microorganism was identified in 14 patients (48.2%). Multimicrobial damage was found in 10 patients. Staphylococcus coagulase negative and Pseudomonas aeruginosa were the most common germs. (Table 2).

Table 1. Distribution of risk factors in our series

| Risk factors | Number of case | Percentage |
|--|-----------------------|-------------------|
| Wearing contact lenses | 7 | 24,1% |
| Eye trauma | 6 | 20,6% |
| History of cataract surgery | 4 | 13,7% |
| Diabetes +/- diabetic retinopathy +/- neovascular glaucoma | 4 | 13,7% |
| Corneal ulcer on dry eye syndrome | 4 | 13,7% |
| Cover on corneal ulcer | 3 | 10,3% |
| Cancer therapy: radio-chemotherapy for bladder cancer or intensity-modulated radiotherapy for cavum cancer | 2 | 6,8% |
| Self-medication by eye drops containing corticosteroids | 2 | 6,8% |
| Not found | 2 | 6,8% |

Table 2. Distribution of germs in our series

| Germs | Number of case | Percentage |
|----------------------------------|-----------------------|-------------------|
| Coagulase-negative staphylococci | 6 | 20,6% |
| <i>Pseudomonas aeruginosa</i> | 6 | 20,6% |
| <i>Staphylococcus aureus</i> | 5 | 17,2% |
| <i>Enterococcus</i> species | 2 | 6,8% |
| <i>Neisseria</i> species | 1 | 3,4% |
| <i>Streptococcus</i> | 1 | 3,4% |
| <i>Haemophilus</i> species | 1 | 3,4% |
| <i>Bacillus cereus</i> | 1 | 3,4% |
| <i>Serratia marcescens</i> | 1 | 3,4% |
| <i>Candida albicans</i> | 1 | 3,4% |
| <i>Streptococcus pyogenes</i> | 1 | 3,4% |
| Sterile samples | 15 | 51,7% |

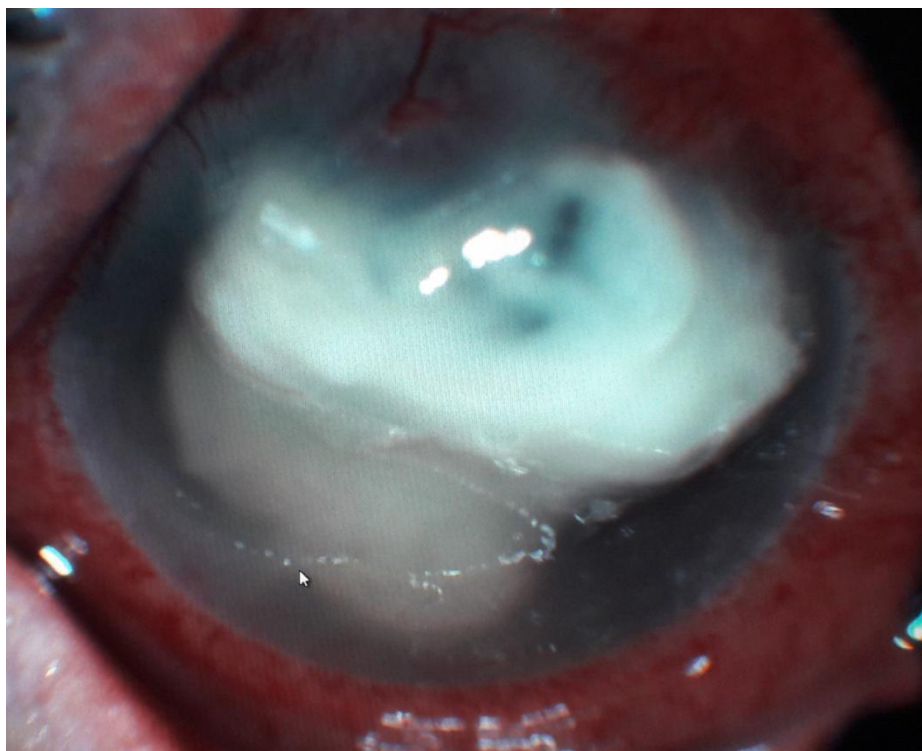


Fig. 1. Large central corneal abscess

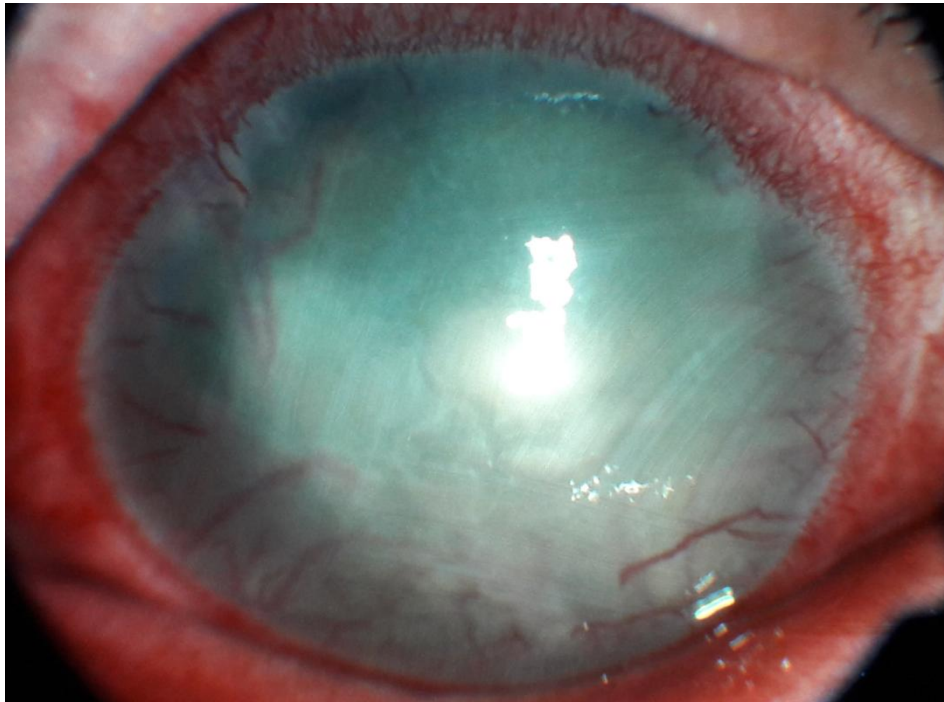


Fig. 2. Central corneal flap with neovascularization

4. EVOLUTION

The average length of hospital stay was 19 days (extremes from 7 days to 27 days) and the average follow-up of patients was 6 months. Two patients were lost to follow-up.

The complications observed were: corneal perforation in 6 patients, corneal neovascularization (Fig. 2) in 12 patients, and a disabling corneal opacification in 21 patients.

For 4 patients the light perception was negative at admission. For 5 others, the infection did not have impact on visual acuity with two of them recovering 10/10. For 16 patients the visual acuity remained reduced (between positive light perception to 01/10).

Eight patients were programmed for a therapeutic penetrating keratoplasty. 4 patients needed evisceration.

5. DISCUSSION

This study included severe corneal abscesses that required hospitalization excluding cases of corneal abscesses that responded well to ambulatory treatment.

In our series corneal abscesses affect all age groups, with a predilection of the adult whose

age varies between 16 and 74 years, and with a slight male predominance, 16 men for 13 women (sex-ratio=1.2). These results are consistent with the data in the literature [6].

Risk factors are identifiable in more than 9/10 cases (90%) in large series [3] (27/29 cases (93.1%) in our series). They vary from one region to another. Indeed, eye trauma is the leading cause of corneal abscess in developing countries, 65.4% in southern India [6] while hydrophilic soft lens wear is the leading cause in industrialized countries [7], 52% in the United States [8] and 26% in New Zealand [5].

In our series the wearing of contact lenses (24.1%) and eye trauma (20.6%) are the most frequent causes and in 3rd place (13.4%) cataract surgery, corneal ulcer on dry eye syndrome and diabetes complicated diabetic retinopathy or not, in 4th place the pillowcases on ulcer of cornea, and the other risk factors also identified were immunosuppression on cancer and self-medication with eye drops containing corticosteroids.

Our germ isolation rate was 48.2% close to that of the American series (53% to 73%) [2]. The relative frequency of the different bacteria responsible for corneal abscess varies greatly from one region to another [5]. Pseudomonas is

the most common bacterium in Bangladesh (30%) [9] (1983), Taiwan (37.7%) [10] (2004) and France (29.2%) [2] (2006), *Staphylococcus aureus* in India (65%) [11] (1983), *Streptococcus pneumoniae* in South Africa (38%) [12] (1985). In our series staphylococcus coagulase negative is the most incriminated germ (20.6%), compared to the results of the study by Bourcier et al, whose staphylococcus coagulase negative was isolated in one third of cases [13], *Pseudomonas aeruginosa* was also the most incriminated germ in our series with the same percentage (20.6%) (only contact lens wearers).

The treatment was based on intensive topical antibiotic therapy including a loading dose and a maintenance dose. Since these are vision threatening abscesses, we have given as a first-line treatment after corneal sampling of fortified eye drops, prepared extemporaneously, vancomycin 50 mg/ml (against gram-positive) and ceftazidime 20 mg/ml (against gram-negative), the treatment is adjusted afterwards according to the results of the antibiotic susceptibility test. The indication for systemic antibiotic therapy should only be considered if there is a risk of generalization of an infection with an ocular starting point or if corneal perforation raises concerns about the spread of the infection [5].

The use of local corticosteroids (subconjunctival) is a controversial issue: they are very useful to reduce the extent of stromal scars and synechia. They were prescribed only when the infection is under control, and under strict ophthalmological supervision.

The unfavourable functional evolution was due to the delay in consultation after the onset of functional symptomatology (mean time of 7 days from 2 days to 14 days), but also to the importance of the inflammatory reaction of the anterior chamber, the virulence of the germ and the initial poor visual acuity.

6. CONCLUSION

Corneal abscess is a serious disease, which remains a main cause of corneal blindness as 16 of our patients had a low final visual acuity, and even 4 needed evisceration. It can be secondary to bacteria and/or fungal and/or amoebic origin even if our study didn't isolate any of it. The prevalence of this condition is constantly increasing. The management of corneal abscesses is difficult, it is a therapeutic

emergency and based on a prior analysis of risk factors, mode of infection and an adapted isolation for the germ in question. Hospitalization is often necessary to ensure the rapid initiation of optimal treatment and close monitoring.

7. LIMITATION OF THE STUDY

The limits of our study reside intrinsically foremost in its retrospective and descriptive type, resulting in incorporating selection biases. In addition, sometimes incomplete records and extraction of data represent a major bias in order to draw the most representative profile of our corneal abscesses.

CONSENT

As per international standard, patient's written consent has been collected and preserved by the author(s).

ETHICAL APPROVAL

As per international standard, ethical approval has been collected and preserved by the author.

COMPETING INTERESTS

Authors have declared that no competing interests exist.

REFERENCES

1. Wong T, Ormonde S. Severe infective keratitis leading to hospital Admission in New Zealand. *Br. J Ophthalmol.* 2003;87: 1103-8.
2. Kerautre TJ, Raobela L, Colin J. Kératites bactériennes Sévères: Étude rétrospective clinique et microbiologique. *J Fr Ophthalmol.* 2006;29:883-888.
3. Limaie R, Maghaie F. Les abcès graves de la cornée: À propos de 100 cas. *J Fr Ophthalmol.* 2007;30(4):374-379.
4. Sharma N. Corneal ulcers. Diagnosis and management. New Delhi, Jaypee; 2008.
5. Baklouti K, Ayachi M. Les abcès cornéens présumés d'origine Bactérienne. *Bull. Soc. Belge Ophthalmol.* 2007;305:39-44.
6. Neumann M, Sjostrand J. Central microbial keratitis in a Swedish city population. A three year prospective study in Gothenburg. *Acta Ophthalmol Copenh.* 1993;71:160-4.
7. Verhelst D, Koppen C, Van Looveren J. The Belgian Keratitis study group. *Bull Soc belge Ophthalmol.* 2005;297:7-15.

8. Erie JC, Nevitt MP, Hodge DO, Incidence of ulcerative keratitis in a defined population from 1950 through 1988. Arch Ophthalmol. 1993;111:1665-71.
9. Katz NN, Wadud SA, Ayazuddin M. Corneal ulcer disease in Bangladesh. Ann Ophthalmol. 1983;15:834-836.
10. Chien-Fan F, Chia-Hui T, Fung-Rong H. Clinical characteristics of Microbial keratitis in a university hospital in Taiwan. Am J Ophthamo. 1983;15:834-836.
11. Mahajan VM. Acute bacterial infections of the eye: Their etiology and treatment. Br J Ophthalmol. 1983;67:191-194.
12. Carmichael TR, Wolpert M, Koornhof HJ. Corneal ulceration at An urban African hospital. Br J Ophthalmol. 1985;69:920-926.
13. Bourcier T, Thomas F, Borderie V, Chaumail C, Bacterial keratitis: Predisposing factors, clinical and microbiological review of 300 cases. Br J Ophtalmol. 2003;87:834-8.

© 2019 Zerrouk et al.; This is an Open Access article distributed under the terms of the Creative Commons Attribution License (<http://creativecommons.org/licenses/by/4.0>), which permits unrestricted use, distribution, and reproduction in any medium, provided the original work is properly cited.

Peer-review history:

The peer review history for this paper can be accessed here:
<https://sdiarticle4.com/review-history/51845>