



Osteonecrosis Related to the use of Osteoporosis Medications: An Integrative Literature Review

Rafaela Melo Santos ^{a++*},
Edson Vinicius Santos Almeida ^{a++},
Naiara Lima Fagundes ^{a++}, Laila Eduarda Silva Pires ^{a++}
and Luiz Eduardo de Góes Ladeia ^{a#}

^a FAINOR, Vitória da Conquista, Bahia, Brazil.

Authors' contributions

This work was carried out in collaboration among all authors. All authors read and approved the final manuscript.

Article Information

DOI: <https://doi.org/10.9734/jammr/2024/v36i65453>

Open Peer Review History:

This journal follows the Advanced Open Peer Review policy. Identity of the Reviewers, Editor(s) and additional Reviewers, peer review comments, different versions of the manuscript, comments of the editors, etc are available here: <https://www.sdiarticle5.com/review-history/117284>

Original Research Article

Received: 11/03/2024

Accepted: 15/05/2024

Published: 21/05/2024

ABSTRACT

Aims: Understand the relationship between bisphosphonates used in the treatment of osteoporosis and mandibular osteonecrosis, its outcomes, and implications for patient management, seeking to understand the best strategies for preventing and managing this condition.

Study Design: Integrative literature review.

Methodology: The research methodology was outlined as exploratory and qualitative, aiming to provide a deeper understanding of the problem under study and generate hypotheses. Works published in the last 10 years (2014 to 2024) were used, including books, articles, periodicals, and online resources. For the selection of the sample, priority was given to works indexed in national

⁺⁺ Dentistry Undergraduate Student;

[#] Dentistry Professor;

*Corresponding author: E-mail: rafa.melo.vca@gmail.com;

and international journals, available in full. The electronic search was conducted in databases such as Latin American and Caribbean Health Sciences Literature (LILACS), Medical Literature Analysis and Retrieval System Online (MEDLINE), and Scientific Electronic Library Online (SciELO). The descriptors used were "Antiresorptive", "Bisphosphonate", "Mandible" and "Bone necrosis", registered in the Health Sciences Descriptors (DeCS), combined with the Boolean operators "AND" and "OR". The inclusion criteria for the selection of articles were to be original, addressing the theme of the study, to be indexed in the selected databases, written in Portuguese or English, and to be free of charge. Studies that were not related to the theme, duplicates and that did not fit into the proposed analysis period were excluded.

Results: Through the studies surveyed, an association between the incidence of osteonecrosis and the use of osteoporosis drugs, such as bisphosphonates, especially osteonecrosis of the jaws (ONJ), was observed. Bisphosphonates, widely used in the treatment of osteoporosis, inhibit bone resorption, but their long-term use is associated with complications, including ONJ. Risk factors such as advanced age, long-term use of medications, comorbidities such as diabetes, and genetic predisposition have been identified.

Conclusion: Management of ONJ involves conservative therapies and surgical procedures, which are especially effective when the condition is diagnosed early. On the other hand, therapeutic alternatives, such as photodynamic therapy, are being investigated, highlighting the need for controlled clinical trials to determine their efficacy.

Keywords: Bisphosphonates; osteonecrosis; osteoporosis; mandible; antiresorptive.

1. INTRODUCTION

Osteoporosis is a bone condition characterized by fragility and increased risk of fractures and is a silent and multifactorial disease. It is characterized by the reduction of bone mass and the deterioration of tissue integrity and structure due to an imbalance in the bone remodeling process [1].

One of the therapeutic approaches for patients with confirmed osteoporosis and high risk of fracture are drugs that will act by stimulating bone formation and preventing tissue loss. There are different medication options, among them, bisphosphonates are highlighted for their ability to increase bone mass. However, prolonged use of bisphosphonates has been associated with possible risk factors for osteonecrosis [1].

Osteonecrosis is characterized by the death of a bone segment due to loss of blood supply, which is an avascular necrosis. This condition can cause pain, limitation of movement, joint collapse, and secondary osteoarthritis [2]. According to Fleish (1996), bisphosphonate interferes with the metabolism of bone tissue, inhibiting resorption and decreasing bone turnover. When necrotic bone is exposed to the oral environment, associated with the accumulation of bisphosphonate induced or physiological trauma, tissue repair does not occur properly [3].

This situation is particularly conducive in the jaw bones, due to specific characteristics such as mucosal lining, frequent risk of infection, and constant potential for trauma [4].

As far as is known, there are few studies that establish the relationship between medications for the treatment of osteoporosis and mandibular osteonecrosis, so it is essential for the dentist to understand and know this relationship in advance, as it will determine the professional's conduct, reaffirming its importance for the identification, treatment, prevention measures of this condition.

From this context, this study aimed to understand the relationship between bisphosphonates used in the treatment of osteoporosis and mandibular osteonecrosis, their outcomes, implications for patient management, seeking to understand the best strategies for prevention and management of this condition.

It is essential that the dental surgeon adopts a diligent posture in the management of patients with osteoporosis undergoing bisphosphonate therapy, especially when faced with invasive dental procedures. Such an approach requires a meticulous anamnesis, the careful request of laboratory tests, such as CTX, aiming at an accurate assessment of the risk involved, as well as the adoption of appropriate and specific therapeutic approaches essential to prevent complications such as osteonecrosis.

2. MATERIALS AND METHODS

The research methodology was outlined as exploratory and qualitative, aiming to provide a deeper understanding of the problem under study and generate hypotheses. The theoretical approach was employed to search for relevant citations that would support and illustrate the theme. The research was conducted through an integrative literature review. Works published in the last 10 years (2014 to 2024) were used, including books, articles, periodicals, and online resources.

For the selection of the sample, priority was given to works indexed in national and international journals, available in full. The electronic search was conducted in databases such as Latin American and Caribbean Health Sciences Literature (LILACS), Medical Literature Analysis and Retrieval System Online (MEDLINE), and Scientific Electronic Library Online (SciELO). The descriptors used were "Antiresorptive", "Bisphosphonate", "Mandible"

and "Bone necrosis", registered in the Health Sciences Descriptors (DeCS), combined with the Boolean operators "AND" and "OR".

The inclusion criteria for the selection of articles were to be original, addressing the theme of the study, to be indexed in the selected databases, written in Portuguese or English, published between the years 2014 and 2024, and to be free of charge. Studies that were not related to the theme, duplicates and that did not fit into the proposed analysis period were excluded.

This methodological approach was adopted with the objective of ensuring the quality and relevance of the data obtained to answer the research questions: which medications for the treatment of osteoporosis can trigger mandibular osteonecrosis, what is the role of the dentist in the identification and treatment of mandibular osteonecrosis, and what measures can be adopted to prevent this condition. The flowchart in Fig. 1 shows the steps for selecting the jobs found.

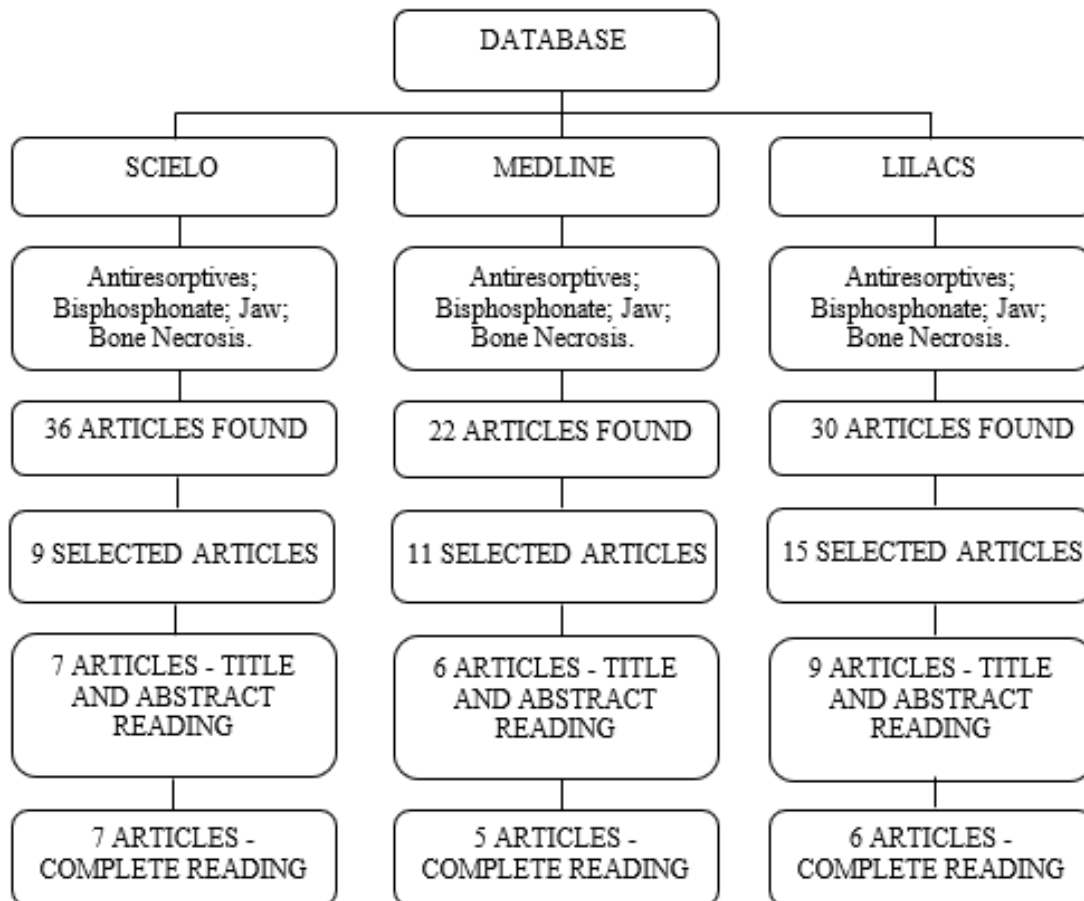


Fig. 1. Flowchart of the selected articles

3. RESULTS AND DISCUSSION

From the bibliographic research carried out, 18 scientific articles that fit the adopted criteria were selected. From the studies found and selected, a survey of the main findings and conclusions relevant to the area was carried out. Table 1 below presents a summary of the most relevant findings of each of these studies.

From the analysis of the literature presented, it was seen that osteonecrosis is a debilitating condition that results in the death of bone tissue due to the interruption of blood supply. Recently, an increase in the incidence of osteonecrosis associated with the use of osteoporosis drugs, especially bisphosphonates, has been observed.

According to Marx et al. osteonecrosis of the jaws (ONJ) is related to the use of osteoporosis medications, especially bisphosphonates [5]. This class of drugs is widely used in the treatment of osteoporosis due to its ability to inhibit bone resorption. However, studies have

shown an association between long-term use of these drugs and the development of osteonecrosis, particularly in the mandible and maxilla. A review study by Marx et al. analyzed cases of osteonecrosis of the jaws related to the use of bisphosphonates and highlighted the importance of early recognition and appropriate management of this complication [5].

Miyazaki et al. state that bisphosphonates are synthetic analogues of endogenous pyrophosphate, which inhibit the activity of osteoclasts, resulting in a reduction in bone resorption. However, studies indicate that this prolonged inhibition of osteoclasts can lead to an imbalance in bone remodeling, predisposing patients to the development of ONJ. In addition, denosumab, a monoclonal antibody that binds to tumor necrosis factor ligand kappa B nuclear factor activating receptor (RANKL), also inhibits bone resorption and may contribute to the occurrence of ONJ due to prolonged suppression of bone turnover [6].

Table 1. Main contributions of selected articles

Title	Author(s)	Publication Year	Main Conclusions
Clinical Practice. Postmenopausal Osteoporosis.	Black D.M., Rosen C.J.	2016	Highlights the need for effective prevention and treatment strategies for postmenopausal osteoporosis, including the impact on bones with the use of bisphosphonates.
Integrated analysis of microRNA and mRNA expression profiles: an attempt to disentangle the complex interactions in osteonecrosis of the femoral head.	Gennari L., Merlotti D., DE Paola V., et al.	2019	Attempted to unravel the complex molecular interactions involved in femoral head osteonecrosis through integrated analysis of gene expression profiles. Bisphosphonates have shown efficacy in preventing osteoporotic fractures in postmenopausal women, but long-term safety requires ongoing evaluation.
Photodynamic therapy: a review of literature in the treatment of oral and maxillofacial lesions.	Girotra, C., Padhye, M., & Mandwe, A.	2018	Photodynamic therapy has shown to be an effective and promising option for treating various oral and maxillofacial lesions, suggesting its inclusion in clinical practices.
Osteonecrosis	Goodman, S. B.	2023	Addresses the causes, symptoms, and treatment options of osteonecrosis. Understanding risk factors and treatment options is crucial for effective management of osteonecrosis and prevention of complications.
	Julia.	2023	Explored the concept of

Title	Author(s)	Publication Year	Main Conclusions
Death of the bone? Find out what osteonecrosis is.			osteonecrosis and its implications for bone health in an accessible and informative manner. Spreading information about osteonecrosis can increase public awareness and promote early diagnosis and treatment.
Osteoporosis treatment: recent developments and ongoing challenges,	Khosla, S., & Hofbauer, L. C.	2017	Reviewed recent developments in osteoporosis treatment and the ongoing challenges associated with this condition. Despite significant advances in osteoporosis treatment, challenges remain in identifying more effective therapeutic strategies and improving access to bone healthcare.
Osteonecrosis of the jaw associated with the use of bisphosphonates: literature review and clinical case report.	Khoury, F., Januario, A. L., & Ferreira, J. D.	2017	Presented a literature review and a clinical case report on jaw osteonecrosis associated with bisphosphonate use. Early recognition and proper management of jaw osteonecrosis are essential to minimize complications and improve clinical outcomes in patients using bisphosphonates.
Risk Factors for Osteonecrosis: A Review of the Literature.	Laffosse, J. M., Tricoire, J. L., Chiron, P., & Molinier, F.	2016	Reviewed the risk factors associated with osteonecrosis, providing important insights for the prevention and management of this condition. Identification and effective management of risk factors are crucial for reducing the incidence and severity of osteonecrosis.
Current perspectives on the etiology of steroid-induced osteonecrosis.	Larsson, S., Bauer, H., & Tomsits, E.	2019	Offered an updated view on the etiology of steroid-induced osteonecrosis. Understanding the underlying mechanisms of steroid-induced osteonecrosis is essential for developing more effective prevention and treatment strategies.
Risk factors for osteonecrosis of the jaw in patients with osteoporosis treated with bisphosphonates: a nested case-control study.	Lipton A., Fizazi K., Stopeck A.T., et al.	2018	Investigated risk factors for jaw osteonecrosis in osteoporosis patients treated with bisphosphonates. Highlighting comorbidities such as diabetes or renal disease as risk factors.
Oral bisphosphonate-induced osteonecrosis: risk factors, prediction of risk using serum CTX testing, prevention, and treatment.	Marx, R. E., Cillo JR, J. E., Ulloa, J. J., & Berger, K. S.	2014	Evaluated risk factors, prevention, and treatment of bisphosphonate-induced osteonecrosis. It was concluded that multidisciplinary management and regular monitoring are crucial to mitigate the risk of osteonecrosis in patients undergoing bisphosphonate treatment.
Denosumab-related	Miyazaki, T.,	2019	Conducted a retrospective study on

Title	Author(s)	Publication Year	Main Conclusions
osteonecrosis of the jaw: A retrospective study of 18 cases in Japan.	Matsunaga, S., Kamioka, H., Sumitani, M., & Amizuka, N.		cases of denosumab-related jaw osteonecrosis. Recognizing and understanding the potential adverse effects of denosumab, such as jaw osteonecrosis, are crucial for guiding clinical practice and improving patient outcomes.
Osteoradionecrosis: A review of pathophysiology, prevention, and pharmacologic management using pentoxifylline, α -tocopherol, and clodronate.	Pambuccian, S.E., Allam, C.K., Venta, L.A., et al.	2018	Reviewed the pathophysiology, prevention, and pharmacological management of osteoradionecrosis, a serious complication of radiotherapy. Preventive and therapeutic strategies, such as the use of pentoxifylline, alpha-tocopherol, and clodronate, play an important role in reducing the risk and treating osteoradionecrosis.
What is Osteonecrosis?	SBQ.	2020	Dissemination of information about osteonecrosis can increase awareness and promote early detection, leading to better clinical outcomes and quality of life for patients.
Atypical subtrochanteric and diaphyseal femoral fractures: second report of a task force of the American Society for Bone and Mineral Research.	Shane E., BURR D., Abrahamsen B., et al.	2014	Apresentou um relatório sobre fraturas subtrocantéricas e diafisárias atípicas do fêmur, destacando sua associação com o uso prolongado de bisfosfonatos.
Pathogenesis of Osteonecrosis of the Jaw: A Review and Update.	Zhang, P., et al.	2016	Presented a report on atypical subtrochanteric and diaphyseal femoral fractures, highlighting their association with prolonged use of bisphosphonates.
Impact of Bisphosphonate-related Osteonecrosis of the Jaw on Osteoporotic Patients after Dental Extraction: A Population-Based Cohort Study	Huang, YF., et al.	2015	Patients with osteoporosis had a significantly higher risk to develop ONJ than healthy persons (adjusted HR, 2.05; 95% confidence interval, 1.58–2.65). The risk of ONJ increased with the severity of osteoporosis, no matter whether patient with cancer or not. A cumulative effect of dental extraction frequency may increase the risk of ONJ.
Bisphosphonate alternative regimens for the prevention of osteoporotic fragility fractures: BLAST-OFF, a mixed-methods study	Sahota, O., et al.	2024	Intravenous zoledronate treatment was generally more acceptable to patients and found to be the most effective bisphosphonate and with greater adherence; however, the cost-effectiveness relative to oral alendronate is limited by its higher zoledronate hospital administration costs.

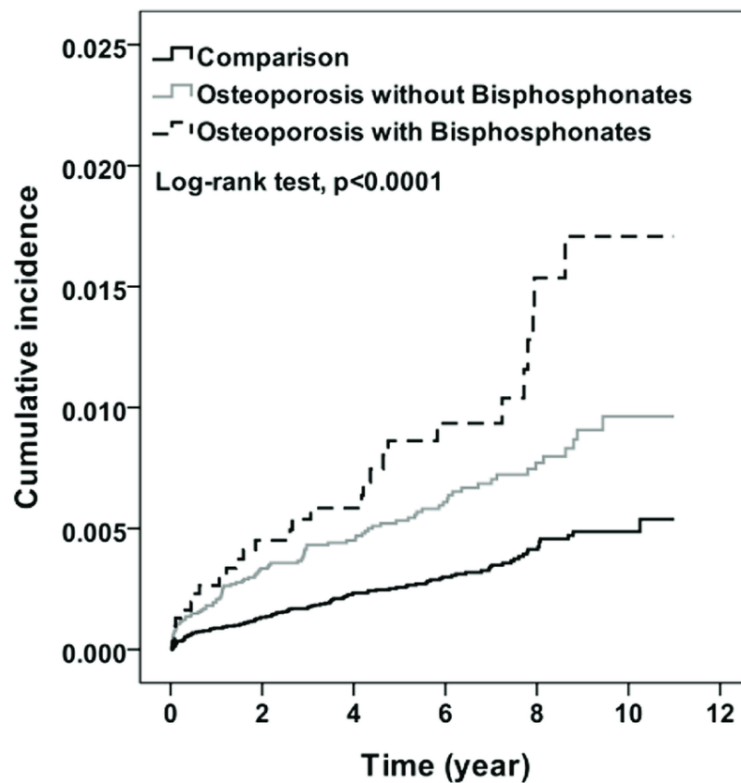


Fig. 2. Cumulative incidence for osteonecrosis by osteoporosis and bisphosphonates (Kaplan-Meier analysis) [7]

Huang et al. sought to know about the risk of developing bisphosphonate-related osteonecrosis of the jaw (BRONJ). They sought to determine the incidence of BRONJ in osteoporotic patients. After 11 years of follow-up, the cumulative incidence of ONJ that increased with the severity of osteoporosis was approximately 0.5% to 1.2% higher among the osteoporosis cohort than among the comparison cohort (Fig. 2) [7].

It is evidenced by Huang et al. and their field research that patients with osteoporosis had a significantly higher risk to develop ONJ than healthy persons (adjusted HR, 2.05; 95% confidence interval, 1.58–2.65). The risk of ONJ increased with the severity of osteoporosis, no matter whether patient with cancer or not. A cumulative effect of dental extraction frequency may increase the risk of ONJ [7].

Through this research, it was seen that some authors still discuss the frequency of presentation of osteonecrosis under certain conditions. Shane et al. reports the low incidence of the complication in patients who use osteoporosis medications, which suggests that the benefits of these medications outweigh the

risks [8]. While Black and Rosen point to the increased incidence of osteonecrosis in specific populations, such as elderly patients or those with underlying medical conditions such as diabetes, kidney disease, autoimmune diseases, among others [9].

Thus, it was possible to observe that risk factors are still widely discussed, which may include advanced age and prolonged use of medications [9], presence of comorbidities such as diabetes or kidney disease [10], and even genetic predisposition [11]. The disease affects more men, usually between the ages of 30 and 65 [12], especially those who use corticosteroids for prolonged periods, abuse alcohol, or have clotting disorders [13]. About 20% of cases do not have an identifiable cause [14]. Laffosse et al. also presented conditions such as chemotherapy, Caisson's disease, sickle cell anemia, among others, as risk factors that increase the risk of osteonecrosis [15].

Based on the framework surveyed, it was found that different authors may offer different interpretations of the mechanisms by which osteoporosis medications can contribute to the development of osteonecrosis. Shane et al.

addresses the suppression of bone remodeling as a possible mechanism involved in the development of bone complications, such as atypical fractures associated with long-term use of bisphosphonates [8]. Meanwhile, Khosla and Hofbauer discuss the direct effects of osteoporosis drugs on bone tissues, such as the long-term use of bisphosphonates associated with excessive suppression of bone remodeling, which can lead to a weakening of bones and increase the risk of atypical fractures [16].

In conditions of low oxygenation and vascularization, bone exposure is common, which increases the risk of severe infections [17], which can lead to osteonecrosis, where part of the bone dies due to lack of blood supply, resulting in structural and functional changes [13]. Factors such as traumatic injuries, excessive alcohol consumption, and long-term use of corticosteroids are associated with the development of osteonecrosis, as they promote the interruption of blood flow [18].

Management of ONJ related to the use of osteoporosis medications remains a clinical challenge. The therapeutic approach varies according to the severity of the condition, ranging from conservative therapy, including antibiotics, antimicrobial mouthwashes, and removal of necrotic tissue, to more invasive surgical procedures, such as surgical debridement and bone reconstruction [19].

Although discontinuation of the drug is often recommended, there is no consensus on the optimal treatment for this condition. Photodynamic therapy has been proposed as a promising approach for the treatment of osteonecrosis of the jaws, offering an alternative to invasive surgical procedures. The review study by Girotra et al. evaluated the efficacy of photodynamic therapy in the treatment of osteonecrosis of the jaws and highlighted the need for controlled clinical trials to determine its role in the management of this condition [19].

Surgical procedures, such as decompression to relieve pressure within the affected bone to allow blood circulation, are performed to preserve the joints and may be more effective if osteonecrosis is diagnosed early [20]. In advanced and persistent cases, partial or total replacement of the affected bone may be necessary [14].

While much progress has been made in understanding ONJ related to osteoporosis drug

use, there are still significant gaps in knowledge, especially regarding precise pathogenic mechanisms and the identification of predictive biomarkers. In addition, the development of more effective and personalized therapeutic strategies remains a pressing need in the field.

Sahota et al. explored the views of patients, doctors, and stakeholders about bisphosphonate alternative regimens for the prevention of osteoporotic fragility fractures. Intravenous zoledronate treatment emerged as a preferred option, owing to its perceived simplicity in adherence, although a subset of patients on alendronate expressed satisfaction with their current regimen. Zoledronate administered intravenously exhibited superior efficacy, boasting higher adherence rates in comparison to other bisphosphonates, thereby mitigating the risk of fragility fractures. However, the cost-effectiveness of oral bisphosphonates surpassed that of intravenous zoledronate, attributed to the substantial expenses associated with hospital-administered zoledronate. The imperative of involving patients and healthcare professionals in delineating research priorities is underscored. Crucial research domains encompass patient-related determinants influencing treatment preference and efficacy, strategies for optimizing long-term care, and exploring the cost-effectiveness of alternative, non-hospital settings for zoledronate delivery [21].

Hyperbaric chamber (CHB) therapy has been explored as an adjunctive therapeutic approach in the treatment of osteonecrosis. CHB involves exposing the patient to oxygen at a pressure greater than atmospheric in a specially designed chamber. CHB can help stimulate the formation of new blood vessels (angiogenesis) at the affected site, promoting revascularization of necrotic bone tissue.

In addition, it can promote the reduction of inflammation by decreasing the expression of inflammatory mediators and improving the local immune response, this helps to accelerate the healing of wounds associated with osteonecrosis, helping to regenerate bone tissue, and reducing the risk of complications such as secondary infections [22].

4. CONCLUSION

Therefore, through the studies surveyed, an association between the incidence of osteonecrosis and the use of osteoporosis drugs,

such as bisphosphonates, especially osteonecrosis of the jaws (ONJ), was observed. Bisphosphonates, widely used in the treatment of osteoporosis, inhibit bone resorption, but their long-term use is associated with complications, including ONJ. The studies discuss the association between these drugs and the development of ONJ, highlighting the importance of early recognition and appropriate management of this complication. Authors differ on the mechanisms by which osteoporosis drugs contribute to osteonecrosis, with some highlighting the suppression of bone remodeling and others the direct effects on bone tissues.

In addition, concluded that ONJ is caused by a few factors. Osteoporosis and past dental history play the very important roles, while BPs play the synergistic effect. Risk factors such as advanced age, long-term use of medications, comorbidities such as diabetes, and genetic predisposition have been identified. Management of ONJ involves conservative therapies and surgical procedures, which are especially effective when the condition is diagnosed early. On the other hand, therapeutic alternatives, such as photodynamic therapy, are being investigated, highlighting the need for controlled clinical trials to determine their efficacy.

Crafting a tailored treatment regimen for bisphosphonate (BPs) recipients following a comprehensive risk assessment can effectively mitigate the occurrence of osteonecrosis of the jaw (ONJ). Emphasizing diligent oral hygiene practices to diminish the need for dental extractions emerges as a paramount strategy in ONJ prevention. Moreover, prior to initiating BPs therapy, thorough examination of the oral cavity to identify and address any existing or potential dental concerns is imperative. Upholding optimal oral hygiene standards stands as a cornerstone principle in averting bisphosphonate-related osteonecrosis of the jaw (BRONJ) among osteoporosis patients.

CONSENT AND ETHICAL APPROVAL

It is not applicable.

ACKNOWLEDGEMENTS

To our esteemed advisor professor for his guidance and continuous support during this work, which were fundamental to our academic growth.

To FAINOR Educational Institution for providing a stimulating learning environment and exceptional resources. Our gratitude to the institution for its commitment to educational excellence and for contributing to our personal and professional development.

COMPETING INTERESTS

Authors have declared that no competing interests exist.

REFERENCES

1. BRATS – Brazilian bulletin of health technology assessment. Efficacy and safety of long-term bisphosphonates for prevention of osteoporotic fractures in postmenopausal women. *BRATS*. 2013;21(7).
2. Bagan JV, Murillo J, Jimenez Y, Poveda R, Milian MA, Sanchis JM. Avascular jaw osteonecrosis in association with cancer chemotherapy: series of 10 cases. *J Oral Pathol Med*. 2005;34:120-3.
3. Fleisch HA. Bisphosphonates: Mechanisms of action. *Endocrine Reviews*. 1996;17(3):235-251.
4. Migliorati CA, Schubert MM, Peterson DE, Seneda LM. Bisphosphonate-associated osteonecrosis of mandibular and maxillary bone: an emerging oral complication of supportive cancer therapy. *Cancer*. 2005;104(1):83–93.
5. Marx RE, Cillo JR, Ulloa JJ, Berger KS. Oral bisphosphonate-induced osteonecrosis: Risk factors, prediction of risk using serum CTX testing, prevention, and treatment. *Journal of Oral and Maxillofacial Surgery*. 2014;72(10):1938-1956.
6. Miyazaki T, Matsunaga S, Kamioka H, Sumitani M, Amizuka N. Denosumab-related osteonecrosis of the jaw: A retrospective study of 18 cases in Japan. *Journal of Bone and Mineral Metabolism*. 2019;37(6):986-993.
7. Huang YF, Chang CT, Muo CH, Tsai CH, Shen YF, Wu CZ. Impact of Bisphosphonate-related Osteonecrosis of the Jaw on osteoporotic patients after dental extraction: A population-based cohort study. *PLoS ONE*. 2015;10(4):e0120756. DOI: 10.1371/journal.pone.0120756
8. Shane E, Burr D, Abrahamsen B, et al. Atypical subtrochanteric and diaphyseal

- femoral fractures: Second report of a task force of the American Society for Bone and Mineral Research. *Journal of Bone and Mineral Research*. 2014;29(1):1-23.
9. Black DM, Rosen CJ. Clinical practice. Postmenopausal osteoporosis. *New England Journal of Medicine*. 2016;374(3):254-262.
 10. Lipton A, Fizazi K, Stopeck AT. Risk factors for osteonecrosis of the jaw in patients with osteoporosis treated with bisphosphonates: A nested case-control study. *Journal of Bone Oncology*; 2018.
 11. Gennari L, Merlotti D, DE Paola V. Integrated analysis of microRNA and mRNA expression profiles: An attempt to disentangle the complex interactions in osteonecrosis of the femoral head. *International Journal of Molecular Medicine*. 2019;43(1):435-449.
 12. SBQ. What is Osteonecrosis? Brazilian Hip Society; 2020. Accessed 29 March 2023. Portuguese. Available: <https://www.sbquadril.org.br/osteonecrose-para-leigos/>>
 13. JULIA. Bone death? Know what osteonecrosis is. Dr. Daniel Souto. ParkMED. 2023. Portuguese. Accessed 29 March 2023. Available: <https://danielsoutoortopedista.com.br/morte-do-osso-saiba-o-que-e-osteonecrose/>>
 14. Goodman, SB. Osteonecrosis. MSD Manuals. Accessed 29 March 2023. Available: <https://www.msmanuals.com/pt-br/casa/dist%C3%BArbios-%C3%B3sseos,-articulares-e-musculares/osteonecrose/osteonecrose>
 15. Laffosse JM, Tricoire JL, Chiron P, Molinier F. Risk factors for osteonecrosis: A review of the literature. *Clinical and Experimental Rheumatology*. 2016;34(3):1-9.
 16. Khosla S, Hofbauer LC. Osteoporosis treatment: Recent developments and ongoing challenges. *The Lancet. Diabetes & endocrinology*. 2017;5(11): 898–907. Available: [https://doi.org/10.1016/S2213-8587\(17\)30188-2](https://doi.org/10.1016/S2213-8587(17)30188-2)
 17. Zhang P, et al. Pathogenesis of osteonecrosis of the jaw: A review and update. *Journal of Oral and Maxillofacial Surgery*. 2016;74(9):1856-1866.
 18. Larsson S, Bauer H, Tomsits E. Current perspectives on the etiology of steroid-induced osteonecrosis. *Orthopedic Research and Reviews*. 2019;11:1-8.
 19. Girotra C, Padhye M, Mandwe A. Photodynamic therapy: A review of literature in the treatment of oral and maxillofacial lesions. *Indian Journal of Dental Research*. 2018;29(6):795.
 20. Khoury F, Januario AL, Ferreira JD. Osteonecrosis of the jaws associated with the use of bisphosphonates: literature review and clinical case report. *Brazilian Journal of Surgery and Implantology*. 2017;5(2):16-21.
 21. Sahota O, Narayanasamy M, Bastounis A, Paskins Z, Bispo S, Langley T, Gittoes N, Davis S, Baily A, Holmes M, Leonardi-Bee, J. Regimes alternativos de bisfosfonatos para a prevenção de fraturas por fragilidade osteoporótica: BLAST-OFF, um estudo de métodos mistos. *Avaliação de tecnologias em saúde (Winchester, Inglaterra)*. 2024;28(21):1–169. Available: <https://doi.org/10.3310/WYPF0472>
 22. Pambuccian SE, Allam CK, Venta LA. Osteoradionecrosis: A review of pathophysiology, prevention, and pharmacologic management using pentoxifylline, α -tocopherol, and clodronate. *Oral Surgery, Oral Medicine, Oral Pathology and Oral Radiology*. 2018;126(4):202-211. DOI: 10.1016/j.oooo.2018.06.073

© Copyright (2024): Author(s). The licensee is the journal publisher. This is an Open Access article distributed under the terms of the Creative Commons Attribution License (<http://creativecommons.org/licenses/by/4.0>), which permits unrestricted use, distribution, and reproduction in any medium, provided the original work is properly cited.

Peer-review history:

The peer review history for this paper can be accessed here:

<https://www.sdiarticle5.com/review-history/117284>