



Osteopenia in HIV Positive Patients After 8 Months on Tenofovir: A Case Study

Karra Geetha ^{a++*}, R. Sakshi ^b, T. Chandana ^b,
Ch. Sai Chandu ^b and T. Ramarao ^{c#}

^a Department of Pharmaceutics, CMR College of Pharmacy, Kandlakoya, Medchal. India.

^b Department of Pharm D, CMR College of Pharmacy, Kandlakoya, Medchal. India.

^c Department of Pharmaceutical Chemistry, CMR College of Pharmacy, India.

Authors' contributions

This work was carried out in collaboration among all authors. All authors read and approved the final manuscript.

Article Information

DOI: <https://doi.org/10.9734/ajarr/2024/v18i7681>

Open Peer Review History:

This journal follows the Advanced Open Peer Review policy. Identity of the Reviewers, Editor(s) and additional Reviewers, peer review comments, different versions of the manuscript, comments of the editors, etc are available here: <https://www.sdiarticle5.com/review-history/117303>

Case Study

Received: 18/03/2024

Accepted: 22/05/2024

Published: 31/05/2024

ABSTRACT

Tenofovir, a nucleotide reverse transcriptase inhibitor, is a key component of highly active antiretroviral therapy (HAART) for HIV infection. While effective in suppressing viral replication, long-term use of tenofovir has been associated with adverse effects, including bone mineral density (BMD) loss and increased risk of osteopenia and osteoporosis. Tenofovir-induced osteopenia is a significant concern in the management of HIV-infected individuals, as it can lead to increased fracture risk and reduced quality of life.

We present the case of a 40-year-old female patient with HIV who was on a Tenofovir disoproxil fumarate (TDF)-containing regimen consisting of Tenofovir disoproxil fumarate, lamivudine, dolutegravir (TLD) for 8 months and developed symptoms suggestive of osteopenia. The patient

⁺⁺ Associate Professor;

[#] Professor;

*Corresponding author: Email: geetabiokarra@gmail.com;

Cite as: Geetha, K., Sakshi, R., Chandana, T., Chandu, C. S., & Ramarao, T. (2024). Osteopenia in HIV Positive Patients After 8 Months on Tenofovir: A Case Study. *Asian Journal of Advanced Research and Reports*, 18(7), 24–29. <https://doi.org/10.9734/ajarr/2024/v18i7681>

presented with difficulty in walking, knee pain and swelling, hip joint pain, and limited left arm mobility, which had significantly impacted her daily activities, leading to her being bedridden for two months. Laboratory findings revealed reduced BMD in the lumbar spine and femoral neck, along with low serum vitamin D levels, supporting the diagnosis of tenofovir-induced osteopenia. The management of tenofovir-induced osteopenia involves discontinuation of TDF and initiation of alternative antiretroviral therapy, as well as supplementation with calcium and vitamin D. In this case, the patient was switched to abacavir, lamivudine, and dolutegravir, which are not associated with significant bone-related side effects. Calcium and vitamin D supplementation were also prescribed to improve bone health. This case highlights the importance of monitoring bone health in patients on TDF therapy and prompt recognition and management of osteopenia to prevent further bone loss and improve quality of life in these patients. Regular assessment of BMD and serum vitamin D levels is essential to detect osteopenia early and initiate appropriate interventions.

Keywords: Tenofovir; osteopenia; antiretroviral therapy; HIV; bone mineral density.

1. INTRODUCTION

Tenofovir, a nucleotide reverse transcriptase inhibitor, is a key component of highly active antiretroviral therapy (HAART) for HIV infection. While effective in suppressing viral-replication, long-term use of tenofovir has been associated with adverse effects, including bone mineral density (BMD) loss and increased risk of osteopenia and osteoporosis [1]. Tenofovir-induced osteopenia is a significant concern in the management of HIV-infected individuals, as it can lead to increased fracture risk and reduced quality of life [2].

2. ETIOLOGY

The etiology of tenofovir-induced osteopenia is multifactorial, involving both direct and indirect effects of the drug. Direct effects include inhibition of osteoblast function and stimulation of osteoclast activity, leading to imbalanced bone remodeling [3]. Indirect effects include renal tubular dysfunction, phosphate wasting, and secondary hyperparathyroidism, which disrupt normal bone metabolism [4]. Other factors such as age, sex, race, and concomitant use of other medications may also influence the development of osteopenia in individuals taking tenofovir [5].

3. EPIDEMIOLOGY

The prevalence of tenofovir-induced osteopenia varies depending on the population studied and the duration of tenofovir exposure. Studies have reported prevalence rates ranging from 10% to 40% in HIV-infected individuals receiving tenofovir-containing regimens [6]. Risk factors for the development of osteopenia in this population

include older age, female sex, low body mass index, and preexisting bone disorders [7].

4. PATHOPHYSIOLOGY

The exact pathophysiology of tenofovir-induced osteopenia is not fully understood. However, several mechanisms have been proposed, including direct effects on bone metabolism and indirect effects mediated through the kidney [8]. Tenofovir is known to inhibit osteoblast function and promote osteoclast activity, leading to accelerated bone resorption and reduced bone formation [9]. Additionally, tenofovir is associated with proximal renal tubular dysfunction, resulting in phosphate wasting and secondary hyperparathyroidism, which further contributes to bone loss [10].

5. CLINICAL MANIFESTATIONS

Tenofovir-induced osteopenia is often asymptomatic in the early stages. However, as bone mineral density decreases, individuals may experience symptoms such as bone pain, fractures (especially in the hip, spine, and wrist), and height loss due to vertebral compression fractures [11]. These symptoms can significantly impact quality of life and mobility in affected individuals.

6. DIAGNOSIS

Diagnosis of tenofovir-induced osteopenia is based on a combination of clinical assessment, bone mineral density (BMD) measurements, and laboratory tests. BMD can be assessed using dual-energy X-ray absorptiometry (DXA), with osteopenia defined as a T-score between -1.0

and -2.5 standard deviations below the young adult mean [12]. Laboratory tests may reveal abnormalities such as elevated serum alkaline phosphatase, parathyroid hormone, and urine N-telopeptide, reflecting increased bone turnover [13].

7. TREATMENT

The management of tenofovir-induced osteopenia involves a combination of lifestyle modifications, pharmacologic therapy, physiotherapy and monitoring. Lifestyle modifications include regular weight-bearing exercise, adequate calcium and vitamin D intake, smoking cessation, and moderation of alcohol consumption [14]. Pharmacologic therapy may include bisphosphonates, denosumab, or teriparatide, which are used to reduce the risk of fractures and improve bone density [15]. Regular monitoring of BMD and clinical symptoms is essential to assess treatment efficacy and adjust therapy as needed [16].

8. CASE PRESENTATION

A 40 years old female patient who is a known case of retroviral disease on tenofovir disoproxil (TDF), lamivudine and dolutegravir (TLD) treatment since 8 months came to the hospital with the complaints of difficulty in walking associated with knee pain and swelling, hip joint pain since 4 months, unable to grab objects, walking with the help of a stick and cannot lift left

hand above shoulder level. The patient was bedridden since 2 months unable to do work by herself. Patient was started on TLD regimen 8 months ago when the CD-4 count was 184 and then started to develop knee pain. On examination the patient was conscious and coherent, temperature-afebrile, blood pressure 120/70mmhg, pulse rate 82 beats per minute, cardiovascular system had S1 S2+, respiratory system had bilateral air entry, per abdomen was soft, oxygen saturation was 98 percent, central nervous system had no abnormal defects and body mass index of 28.1kg/m². The laboratory findings were the haemoglobin level was 12.8 gm/dl, white blood cell count was 4.8 k/cumm, red blood cell count was 4.56*10⁶/cumm, platelet count was 1.78 lk/cumm, CD4 count 420, T score 3.3, Z score 2.9, serum calcium was 9.8, vitamin B12 was 258, vitamin D 23.7. The ultrasound showed the patient has a small kidney with grade 3 recurrent pyogenic cholangitis (RPC). X ray was conducted in the lumbar spine (0.631g/cm², T- SCORE -2.7) and femoral neck (0.804 g/cm², T -score -2.5) revealed reduced bone mineral density. Based on the complaints and the laboratory findings the patient was diagnosed with tenofovir induced osteopenia. The treatment given to the patient was tablet abacavir 300 mg per oral twice a day, tablet lamivudine 150 mg per oral twice a day, tablet dolutegravir 50 mg per oral twice a day, tablet calcium per oral once a day and tablet multivitamin/b-complex per oral once a day.

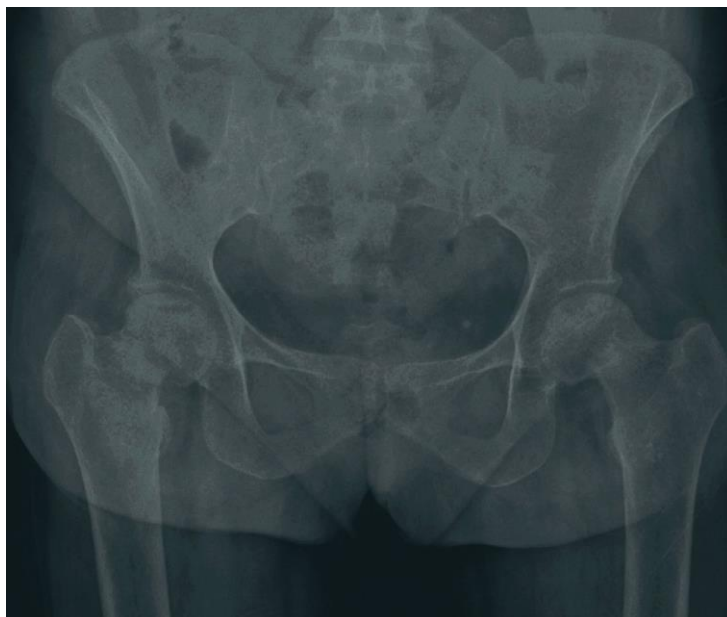

Fig. 1. A pelvic X-ray demonstrating widespread osteopenia in femoral neck

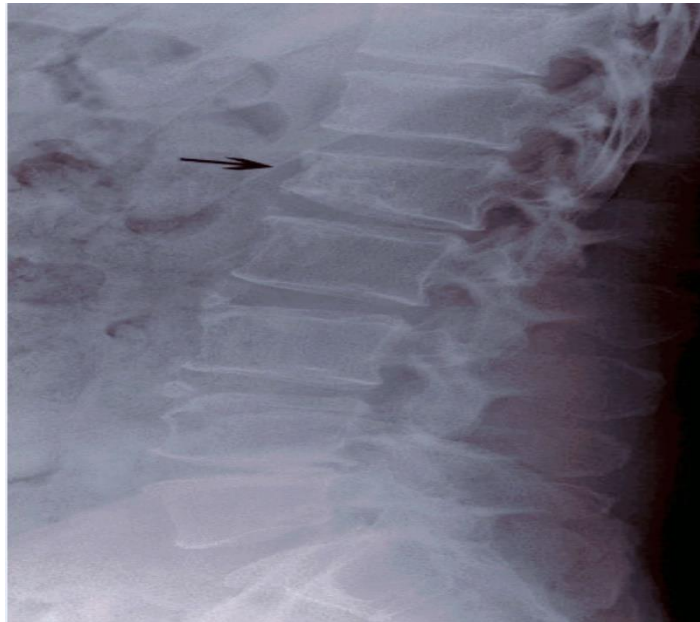


Fig. 2. Lumbar spine X- ray demonstrating osteopenia

9. DISCUSSION

TDF therapy considerably increases the likelihood of BMD loss. Prescriptions containing TDF were linked to a 12% annual increase in fracture risk in a cross-sectional research with 56,660 patients [17]. Age over 50, body mass index under 18.5, and TDF-based treatment were found to be independent risk factors for low BMD in a recent cross-sectional study conducted in China [18].

In this case, a 40-year-old female patient with HIV presented with symptoms suggestive of osteopenia after being on a TLD regimen for 8 months, including tenofovir disoproxil, lamivudine, and dolutegravir, leading to an increase in adverse events related to TDF, including loss of BMD [19]. She complained of difficulty in walking, knee pain and swelling, hip joint pain, and limited left arm mobility, which had significantly impacted her daily activities, leading to her being bedridden for two months.

The patient's laboratory findings revealed a CD4 count of 420, indicating good immunological status. However, her bone health was compromised, as evidenced by reduced bone mineral density in the lumbar spine and femoral neck, indicating osteopenia. Other findings, such as low serum vitamin D levels, also contributed to her bone health issues. According to a meta-analysis released in 2020, there was an initial decrease in bone mineral density following the

start of TDF, which was followed by a stabilising phase. Patients with renal tubular failure have been shown to exhibit progressive bone loss, osteopenia with elevated bone turnover indicators, and fragility fractures. According to reports, a bone biopsy reveals elevated osteoid production, a sign of osteopenia [20].

Tenofovir-induced osteopenia is a well-known side effect of TDF, particularly in patients with HIV. The exact mechanism involves TDF's impact on bone metabolism, leading to increased bone resorption and decreased bone formation. TDF's pharmacological toxicity significantly lowers the kidney's production of active vitamin D. It can also boost the vitamin D binding receptor by 26% and total 1,25-dihydroxyvitamin D levels, lowering free 1,25-dihydroxyvitamin D (the active form) by 42%. This functional vitamin D deficit might cause decreased intestinal calcium absorption. Reduced serum calcium raises PTH levels, which stimulates the conversion of 25-hydroxyvitamin D to 1,25-dihydroxyvitamin D to sustain calcium absorption [21]. TDF can also suppress the activity of the calcium-sensing receptor (CaSR) in a dose-dependent way [22]. Risk factors for TDF-induced bone loss include long duration of TDF therapy, older age, female gender, low body weight, and vitamin D deficiency.

Management of TDF-induced osteopenia includes discontinuation of TDF and initiation of alternative antiretroviral therapy, as done in this

case by switching to abacavir, lamivudine, and dolutegravir. Calcium and vitamin D supplementation are also essential to improve bone health and reduce the risk of fractures.

10. CONCLUSION

In conclusion, this case highlights the importance of monitoring bone health in patients with HIV on TDF therapy. Regular assessment of bone mineral density and serum vitamin D levels can help detect osteopenia early and prevent further bone loss. Prompt recognition and management of TDF-induced osteopenia, including switching to alternative antiretroviral therapy, supplementation with calcium/vitamin D, physiotherapy and lifestyle modifications are crucial to improving bone health and quality of life in these patients.

CONSENT

As per international standards or university standards, patient(s) written consent has been collected and preserved by the author(s).

COMPETING INTERESTS

Authors have declared that no competing interests exist.

REFERENCES

1. McComsey GA, Kitch D, Daar ES, et al. Bone mineral density and fractures in antiretroviral-naive persons randomized to receive abacavir-lamivudine or tenofovir disoproxil fumarate-emtricitabine along with efavirenz or atazanavir-ritonavir: Aids Clinical Trials Group A5224s, a sub-study of ACTG A5202. *J Infect Dis.* 2011;203(12):1791-801.
2. Bedimo R, Maalouf NM, Zhang S, Drechsler H, Tebas P. Osteoporotic fracture risk associated with cumulative exposure to tenofovir and other antiretroviral agents. *AIDS.* 2012;26(7):825-31.
3. Hoy J, Grund B, Roediger M, Schwartz A, Shepherd J, Avihingsanon A, et al. Interruption or deferral of antiretroviral therapy reduces markers of bone turnover compared with continuous therapy: the SMART Body Composition substudy. *J Bone Miner Res.* 2013;28(6):1264-74.
4. Shiau S, Broun EC, Arpadi SM, Yin MT. Incident fractures in HIV-infected individuals: a systematic review and meta-analysis. *AIDS.* 2013;27(12):1949-57.
5. Sharma A, Flom PL, Weedon J, Klein RS. Prospective study of bone mineral density changes in aging men with or at risk for HIV infection. *AIDS.* 2010;24(15):2337-45.
6. Bonjoch A, Figueras M, Estany C, Perez-Alvarez N, Rosales J, del Rio L, et al. High prevalence of and progression to low bone mineral density in HIV-infected patients: a longitudinal cohort study. *AIDS.* 2010;24(18):2827-33.
7. Womack JA, Goulet JL, Gibert C, Brandt C, Chang CC, Gulanski B, et al. Increased risk of fragility fractures among HIV infected compared to uninfected male veterans. *PLoS One.* 2011;6(2):e17217.
8. Ofotokun I, Titanji K, Vikulina T, Roser-Page S, Yamaguchi M, Zayzafoon M, et al. Role of T-cell reconstitution in HIV-1 antiretroviral therapy-induced bone loss. *Nat Commun.* 2015;6:8282.
9. Brown TT, Qaqish RB. Antiretroviral therapy and the prevalence of osteopenia and osteoporosis: a meta-analytic review. *AIDS.* 2006;20(17):2165-74.
10. Grund B, Peng G, Gibert CL, Hoy JF, Isaksson RL, Shlay JC, et al. Continuous antiretroviral therapy decreases bone mineral density. *AIDS.* 2009;23(12):1519-29.
11. Grant PM, Kitch D, McComsey GA, Dube MP, Haubrich R, Huang J, et al. Long-term bone mineral density changes in antiretroviral-treated HIV-infected individuals. *J Infect Dis.* 2016;214(4):607-11.
12. Hansen AB, Gerstoft J, Kronborg G, Larsen CS, Pedersen C, Pedersen G, et al. Incidence of low and high-energy fractures in persons with and without HIV infection: a Danish population-based cohort study. *AIDS.* 2012;26(3):285-93.
13. Triant VA, Brown TT, Lee H, Grinspoon SK. Fracture prevalence among human immunodeficiency virus (HIV)-infected versus non-HIV-infected patients in a large U.S. healthcare system. *J Clin Endocrinol Metab.* 2008;93(9):3499-504.
14. Shiau S, Broun EC, Arpadi SM, Yin MT. Incident fractures in HIV-infected individuals: a systematic review and meta-analysis. *AIDS.* 2013;27(12):1949-57.
15. Brown TT, McComsey GA, King MS, Qaqish RB, Bernstein BM, da Silva BA. Loss of bone mineral density after antiretroviral therapy initiation, independent

- of antiretroviral regimen. *J Acquir Immune Defic Syndr*. 2009;51(5):554-61.
16. Young B, Dao CN, Buchacz K, Baker R, Brooks JT. Increased rates of bone fracture among HIV-infected persons in the HIV Outpatient Study (HOPS) compared with the US general population, 2000-2006. *Clin Infect Dis*. 2011;52(8):1061-8.
 17. Bedimo R, Maalouf NM, Zhang S, Drechsler H, Tebas P. Osteoporotic fracture risk associated with cumulative exposure to tenofovir and other antiretroviral agents. *AIDS*. 2019;26:825-31.
DOI: 10.1097/QAD.0b013e32835192ae
 18. Meng WQ, Chen ML, Song YZ, Zhang H, Xie R, Zhang FJ. Prevalence and risk factors of low bone mineral density in HIV/AIDS patients: A Chinese cross-sectional study. *J ACQ Immun DEF SYND* 2022;90:360-8.
DOI: 10.1097/QAI.0000000000002958 [PubMed] [CrossRef] [Google Scholar]
 19. Gervasoni C, Meraviglia P, Landonio S, Baldell S, Fucile S, Castagnoli L. Low body weight in females is a risk factor for increased tenofovir exposure and drug-related adverse events. *PLoS One*. 2021; 8:e80242.
DOI: 10.1371/journal.pone.0080242
 20. Baranek B, Wang S, Cheung AM, Mishra S, Tan DH. The effect of tenofovir disoproxil fumarate on bone mineral density: a systematic review and meta-analysis. *Antiviral Therapy* 2020;25:21-32. Available: <https://doi.org/10.3851/IMP3346>
 21. Havens PL, Kiser JJ, Stephensen CB, Hazra R, Flynn PM, Wilson CM. Association of higher plasma vitamin d binding protein and lower free calcitriol levels with tenofovir disoproxil fumarate use and plasma and intracellular tenofovir pharmacokinetics: cause of a functional vitamin d deficiency? *Antimicrob Agents CH*. 2013;57:5619-28.
DOI: 10.1128/AAC.01096-13
 22. Mingione A, Maruca K, Chiappori F, Pivari F, Brasacchio C, Quirino T. High parathyroid hormone concentration in tenofovir-treated patients are due to inhibition of calcium-sensing receptor activity. *BioMed Pharmacother* 2018;97:96 9-74.
DOI: 10.1016/j.biopha.2017.11.037

© Copyright (2024): Author(s). The licensee is the journal publisher. This is an Open Access article distributed under the terms of the Creative Commons Attribution License (<http://creativecommons.org/licenses/by/4.0>), which permits unrestricted use, distribution, and reproduction in any medium, provided the original work is properly cited.

Peer-review history:

The peer review history for this paper can be accessed here:

<https://www.sdiarticle5.com/review-history/117303>