

Acute supratentorial bilateral giant extradural haematomas as a postoperative complication of resection of recurrent meningioma at the skull base

Jinlu Yu¹, Kan Xu², Haiyan Huang³

ABSTRACT

We report one rare case of an acute bilateral giant extradural haematoma as a postoperative complication of the resection of recurrent meningioma. The patient underwent meningioma resection at the sellar region five times. The patient recovered well after the first four surgeries. The resection went well during the fifth operation. However, acute supratentorial remote giant epidural haematomas developed in the bilateral hemispheres one hour after the operation, leading to the death of the patient. Therefore, great care must be taken to prevent the occurrence of such haematomas.

KEY WORDS: Skull base, Recurrent meningioma, Resection, Acute epidural haematoma.

Pak J Med Sci April - June 2011 Vol. 27 No. 2 463-465

How to cite this article:

Yu J, Xu K, Huang H. Acute supratentorial bilateral giant extradural haematomas as a postoperative complication of resection of recurrent meningioma at the skull base. Pak J Med Sci 2011;27(2):463-465

Note: Jinlu Yu & Kan Xu contributed equally to the work.

INTRODUCTION

The occurrence of extradural haematomas in supratentorial remote areas after tumor resection usually occurs unilaterally.^{1,2} However, it is extremely rare that acute bilateral extradural haematomas occur in supratentorial remote areas. To date, such cases have rarely been reported in the literature.

CASE REPORT

This case report involved a 39-year-old female patient with a 10-year history of recurrent meningioma at the skull base. Resection of sellar meningiomas was

performed four times. After the fourth operation, loss of vision in the right eye occurred. One year after the fourth surgery, examination showed the left eye vision was reduced (4.2) and temporal hemianopia. Ophthalmoscopy showed primary optic nerve atrophy. MRI revealed abnormal lobular signaling at the sellar region, with an approximate size of 4.0 x 3.2 x 3.1 cm, and T1W1 and T2W1 signals were equal. The bilateral internal carotid arteries were pushed outwards by the tumor in the sellar region. The signal of the tumor became higher after enhanced scanning (Figure 1 A-B). Platelet count and coagulation function were normal. Then resection was performed. The tumor was soft and had a limited blood supply. The base of the tumor was located in the sellar diaphragm. The patients awoke and made movements shortly after the surgery.

However, one hour after the surgery, the patient lost consciousness and lapsed into a mild coma. Emergency head CT examination showed that acute bilateral giant extradural haematomas developed (Figure 1 C-D). Extradural haematoma (60ml on the left side and 50ml on the right side) was immediately evacuated by craniotomy. After removing blood clots, we found that bleeding was more severe in the dura

1. Jinlu Yu, MD,
2. Kan Xu, MD,
3. Haiyan Huang, MD,
1-3: Departments of Neurosurgery,
The First Affiliated Hospital of Jilin University,
Changchun, Jilin, China.

Correspondence:

Haiyan Huang,
Department of Neurosurgery,
The First Affiliated Hospital of Jilin University,
71 Xinmin Avenue, Changchun, Jilin, 130021, China.
E-mail: haiyanhuang@live.cn

* Received for Publication: November 17, 2010

* Accepted: February 15, 2011

matter around the sagittal sinus, no obvious bleeding was found in other regions. However, respiratory and heart failure occurred due to brain herniation two days after the evacuation, leading to the death of the patient.

DISCUSSION

Herein we describe one rare case of acute bilateral giant extradural haematomas as a complication of the resection of recurrent meningioma at the skull base. The occurrence of extradural haematomas is relatively rare after the resection of a tumor at the skull base, and haematomas are usually unilateral when they do occur. It is extremely rare for supratentorial remote site acute extradural haematoma to develop bilaterally after intracranial surgery.¹⁻³

The mechanisms underlying the development of supratentorial remote site extradural haematomas after the resection of intracranial tumors remain unclear. Several hypotheses have been proposed. For example, the loss of a large amount of CSF results in a

reduction of intracranial pressure leading to an increase in the wall pressure of the dura veins; consequently, the regulatory function of the blood vessels is disrupted and blood vessels rupture.^{1,4} Blood from the ruptured blood vessels dissects and separates the dura matter from the bone of the skull to form haematomas. The pressure of the wall of the dura veins is further increased due to the effect of water pressure produced by the haematomas, leading to bleeding and the distension of the haematomas.^{5,6} Stretching of the bridging vein caused by the compressed brain tissue after the loss of CSF and deficient coagulation also may be an important factor for the formation of haematomas.^{4,7}

Based on this hypothesis, remote supratentorial bleeding should occur around the sagittal sinus. Because the dura veins on the cerebral convexity are small and run parallel to the artery between the two layers of the dura matter, the frequency of bleeding is low. However, the anatomy of the dura matter near the sagittal sinus is complicated. The veins on the

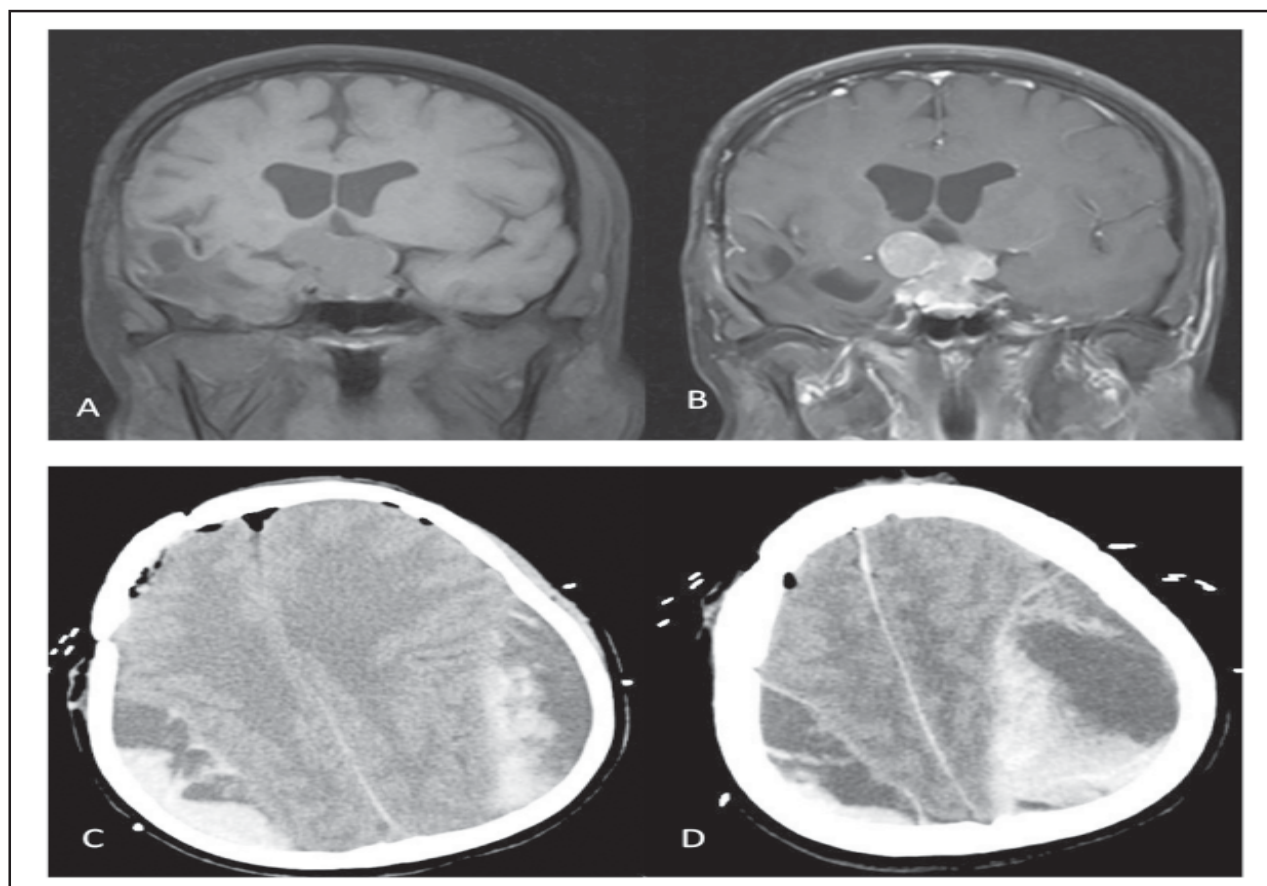


Fig-1: A-B: Preoperative MRI images showing a meningioma in the sellar region with uniform enhancement of the meningioma.

C-D: CT images showing giant extradural haematomas were formed on bilateral temporoparietal areas.

surface of the brain combine into a big bridging vein. Moreover, many arachnoid granules are located around the sagittal sinus, and they are vulnerable to trauma. Due to the loss of a large amount of CSF, an increase in the pressure of the wall of the dura veins easily induces bleeding from these fragile structures. Furthermore, bleeding occurs more in younger patients because the adhesion is loose between the dura matter and the skull bone.^{4,8} Remote supratentorial extradural bleeding after intracranial operation often occurs near the sagittal sinus and in younger patients, and these findings support the hypothesis mentioned above.^{7,9}

The clinical presentation reported in this study was peculiar. A total of five resections of sellar meningiomas were performed. We believe that the occurrence of these haematomas was closely associated with the first four operations. Intracranial blood circulation was disrupted during these operations due to repetitive loss of a large amount of CSF.⁹ When the fifth operation was performed, the loss of a large amount of CSF occurred again. As a consequence, the damaged dura matter could no longer exert its regulatory function, leading to the rupture of blood vessels and the formation of remote site extradural haematomas. We found that bilateral giant extradural haematomas were situated close to the sagittal sinus and that they were symmetrically distributed, thus, we propose the hypothesis of formation of remote supratentorial extradural haematomas, based on the fact that the loss of a large amount of CSF after surgery caused an increase in the pressure of the wall of dura veins near the sagittal sinus, leading to the rupture of blood vessels. Whereas our findings contradict the hypothesis that extradural haematomas form due to stretching of the bridging vein by the compressed brain tissues

after the loss of CSF.^{5,8} However, bilateral extradural haematomas are far more dangerous than unilateral ones, they progress more rapidly, therefore, even if haematoma evacuation is actively performed, the patient's life cannot be saved.

CONCLUSIONS

In patients with multiple resections of intracranial tumors, clinicians must take great care to prevent the occurrence of such haematomas. If they do occur, the prognosis is poor.

REFERENCES

1. Borkar SA, Sinha S, Sharma BS. Remote site epidural haematoma. *J Clin Neurosci* 2009;16(8):1097-1098.
2. Hamlat A, Heckly A, Doumbouya N, Seigneuret E, Brassier G. Epidural hematoma as a complication of endoscopic biopsy and shunt placement in a patient harboring a third ventricle tumor. *Pediatr Neurosurg* 2004;40(5):245-248.
3. Kalfas IH, Little JR. Postoperative hemorrhage: A survey of 4992 intracranial procedures. *Neurosurgery* 1988;23(3):343-347.
4. Eom KS, Kim TY, Park JT. Contralateral acute interdural haematoma occurring after burr hole drainage of chronic subdural haematoma. *Br J Neurosurg* 2009;23(2):213-215.
5. Sinar EJ, Lindsay KW. Distant epidural haematoma complicating removal of frontal tumours. *J Neurol Neurosurg Psychiatry* 1986;49(4):442-4.
6. Mathiesen T, Kakarieka A, Edner G. Traumatic intracerebral lesions without extracerebral haematoma in 218 patients. *Acta Neurochir (Wien)* 1995;137(3-4):155-163.
7. Wolfsberger S, Gruber A, Czech T. Multiple supratentorial epidural haematomas after posterior fossa surgery. *Neurosurg Rev* 2004;27(2):128-132.
8. Landeiro JA, Flores MS, Lapenta MA, Galdino AC, Lázaro BC. Remote hemorrhage from the site of craniotomy. *Arq Neuropsiquiatr* 2004;62(3B):832-834.
9. Tjan TG, Aarts NJ. Bifrontal epidural haematoma after shunt operation and posterior fossa exploration: Report of a case with survival. *Neuroradiology* 1980;19(1):51-53.