

Delayed presentation of colonic perforation after abdominal impalement trauma by sewing needle: A case report and review of literature

Wei Zhang¹, Cun Wang², ZongGuang Zhou³

ABSTRACT

Post-traumatic, delayed colonic perforation is a rare but life-threatening cause of acute abdomen. Delayed presentation of colonic perforation is extremely rare, being observed only in patients after blunt abdominal trauma. We encountered an unusual case of delayed colonic perforation in a patient after abdominal impalement trauma. A 45-year-old man sustained abdominal impalement trauma by sewing needle 12 months ago, without getting timely management, and had a delayed perforation of sigmoid colon later. This case reminds surgeons not to overlook the delayed colonic perforation after abdominal impalement trauma.

KEY WORDS: Delayed perforation, Abdominal trauma, Colon injury, Impalement trauma, sewing needle.

Pak J Med Sci April - June 2011 Vol. 27 No. 2 468-470

How to cite this article:

Zhang W, Wang C, Zhou ZG. Delayed presentation of colonic perforation after abdominal impalement trauma by sewing needle: A case report and review of literature. Pak J Med Sci 2011;27(2):468-470

INTRODUCTION

Delayed presentation of colonic perforation after abdominal trauma is not actually common, and it occurs unexceptionally in patients with blunt abdominal trauma in the literature. Some patients with abdominal trauma were clinically observed that sustained suddenly a colon perforation after eating or during defecation after several days or weeks while they had no symptoms of peritonitis or positive imaging studies at the time of suffering from injury. It is to be noted that some of them sustained only a slight abdominal trauma (e.g. punch or kicks). These

delayed colon perforations received little attention. This case report describes a patient who sustained abdominal impalement trauma by sewing needle 12 months ago, without getting timely treatment, and had a delayed perforation of sigmoid colon later.

CASE REPORT

A 40-year-old man presented to the Emergency Department (ED) complaining of abdominal colicky pain, nausea and vomiting lasting for 24 hours. The patient denied chronic constipation or diarrhea, melena, and did not note any blood in the emesis. On examination, his temperature was 37.2°C, heart rate was 80 beats per minute, blood pressure was 140/77 mm Hg, and the oxygen saturation was 96% on room air. The abdomen was distended, with weak bowel sounds, and abdominal muscle insecurity, tenderness and rebound tenderness complete abdomen. Rectal examination was negative for gross blood. Results of laboratory tests showed leukocytosis with left shift (white cell count, 16630 cells/mm³; segment form, 91.4%), as well as the C-reactive protein is 25.1 mg/dL. An abdomen radiograph revealed a large volume of free air below the right hemidiaphragm and

1. Wei Zhang, MD,
2. Cun Wang, MD,
3. ZongGuang Zhou, MD,
- 1-3: Institute of Digestive Surgery & Dept. of Gastrointestinal Surgery, West China Hospital, Sichuan University, Chengdu, Sichuan Province, China.

Correspondence:

Dr. ZongGuang Zhou,
Institute of Digestive Surgery & Dept. of Gastrointestinal Surgery,
West China Hospital, No.37 on Guo-Xue, Chengdu 610041,
Sichuan Province, China.
E-mail: zhou767@163.com

* Received for Publication: September 27, 2010

* Accepted: January 11, 2010

several sewing needles adhering to left lower quadrant of abdominal wall. (Fig-1)

Additionally, it was learnt, after investigation, that the man suffered a mild illness caused by mental retardation and alcohol abuse. Several impalement traumatic injuries over left lower quadrant of abdomen by sewing needle were observed after a heavy use of alcohol, 12 months ago. Then, he had no complaints, and was not admitted to clinic.

The patient was admitted to the surgery service, and underwent laparotomy. An approximately 2-cm perforation was found at antimesenteric border of the proximal sigmoid colon, through which the feces was flowing into the left anterior pelvic cavity. Six residual segments of rusty sewing needle adhered to the left lower quadrant of abdominal wall, and three whole segments of rusty sewing needle adhered to the omentum. These segments of sewing needle were removed from abdominal wall and the omentum (Fig-1), and colostomy was performed. The patient made uneventful postoperative recovery.

DISCUSSION

As is well known, most of patients with penetrating abdominal wounds require surgical exploration as soon as possible. The incidence of colonic perforation is far less in blunt abdominal trauma than in penetrating trauma. However, delayed presentation of colonic perforation occurs rarely in patients with abdominal penetrating trauma. The EAST Multi-Institutional Hollow Viscus Injury (HVI) Study reported a 1.1% incidence of HVI and 0.15% incidence of isolated colon injury in patients with blunt abdominal trauma.¹ Although rare, these injuries have serious consequences. Patients with colon injury have higher complication and readmission rates and higher mortality rates (19.8%) compared to patients with similar injury severities without colon injury (12.2%).² Also, delayed perforations occur frequently and pose a diagnostic challenge to the attending surgeon. On our review of the literature, delayed perforation of colon has been rarely reported; however, there is a lack of consistency in reports on timeframe after abdominal trauma. There were some cases of 24h or several days, rarely exceeding a week.^{3,4} Such a case of delayed perforation of sigmoid colon after abdominal impalement trauma has never been reported. Idiopathic perforation should be in absence of trauma or Valsalva maneuver^{5,6}, and stercoral perforation may feature chronic constipation and hard stools as part of its cause.⁷ Our patient did not have any risk factors causing idiopathic perforation and stercoral perforation noted in previous publications. This information sup-

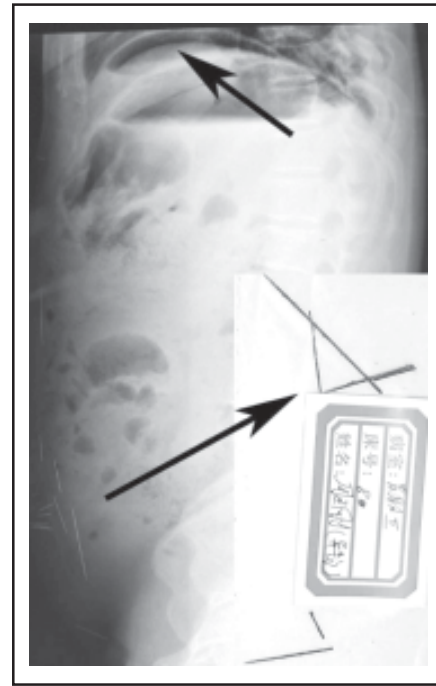


Figure-1: Abdomen radiograph showing a large volume of free air below the right hemidiaphragm and several sewing needles over left lower quadrant of abdomen and segments of sewing needle from abdominal wall and the omentum (arrow).

ports a diagnosis of post-traumatic, delayed colonic perforation in our patient.

Two possible etiologies for the post-traumatic, delayed perforation of colon have been suggested. First, disadvantages of sigmoid colon anatomy exist. According to the literatures⁸⁻¹⁰, there are several weak points in the colonic vasculature including: the splenic flexure or Griffith's point; the rectosigmoid region, or Sudeck's point; and the ileocecal region. These watershed areas are more vulnerable to ischemic injury than other parts. Second, Bowel may be crushed between rigid objects (e.g. spine or pelvis and automobile components), with subsequent contusion, vascular compromise, and necrosis. Shearing forces between fixed and mobile portions of the gastrointestinal tract can cause laceration of bowel wall or mesenteric vessels.¹¹ Our patient may have sustained small punctured wound of sigmoid colon wall or mesenteric vessels 12 months ago. Then, persistent friction between colon wall or mesenteric vessels and intra-abdominal sewing needles may have caused abrasion, vascular compromise and chronic colitis, with subsequent necrosis and ulcer of colon wall. High intraluminal pressure of the sigmoid colon during defecation easily causes perforation of sigmoid colon with pathologic changes.

The diagnosis of colon injury is very difficult and mostly delayed after trauma. Isolated colon injury may initially have nonspecific physical findings.¹¹ Also, abdominal contusion increasing abdominal pain, generalized or local peritonitis can hinder the evaluation of colon injury. Additionally, gross blood on rectal examination greatly increases the likelihood of colon injury. So, the overall reliability of the physical examination is limited and it often confuses surgeon.¹² Routine laboratory testing with leukocytosis seems to have little utility for the diagnosis of colon injury.¹³

There is rarely free air on abdomen radiograph in patients without full thickness colon injury, but is actually common in those with perforation.¹⁴ Similarly, although recent research showed that computed tomography (CT) had 97% sensitivity and 96% specificity for a full thickness colon injury,¹⁴ pathognomonic signs are rarely visualized on CT in those patients without perforation, and they are present in a majority of colon injuries. CT can increase the sensitivity for perforation compared to abdomen radiograph, but its ability to rule out non-full thickness colon injuries is limited. Although in recent series, focused assessment with sonography for trauma (FAST) has satisfying performance for detecting free intra-abdominal fluid (the volume of fluid > 100cc), but there is a situation that occurs less frequently with colon injuries.¹⁵⁻¹⁷ For application of FAST and CT scan in the evaluation of abdominal trauma, diagnostic peritoneal lavage (DPL) is no longer the preferred option clinically. However, DPL is significantly useful in prompting laparotomy for hemodynamically unstable patients when both FAST and CT are obviously not conforming with the worsening of condition of patients or neither is unavailable.¹⁸

The optimal management of post-traumatic colon perforation is surgical intervention with appropriate antibiotics as soon as the diagnosis is made. Resection of the involved colon and proximal colostomy is the treatment of choice. Intraoperatively, clearing away intra-abdominal foreign body thoroughly may avoid second perforation and further complications. In conclusion, patients who experience abdominal trauma with a positive diagnostic study (DPL, FAST, or CT scan) or peritonitis on physical examination, indicating hollow viscus perforation, should undergo urgent laparotomy. Patients without peritonitis on physical examination and positive imaging studies pose a more difficult challenge. And we recommend that those with risk factors causing idiopathic perforation and stercoral perforation (e.g. chronic constipation), even though sustain slight abdominal trauma, should be observed closely, and intra-abdominal

foreign body in patients after abdominal trauma should be cleared away just in time.

This report highlights the importance of being aware of delayed perforation of colon after abdominal impalement trauma. It also suggests that surgeon should clear away intra-abdominal foreign body (e.g. needle) in time to avoid delayed presentation of colonic perforation. Thus, surgeons should not overlook this rare but potentially fatal disease.

REFERENCE

1. Williams MD, Watts D, Fakhry S. Colon injury after blunt abdominal trauma: results of the EAST Multi-Institutional Hollow Viscus Injury Study. *J Trauma* 2003;55(5):906-912.
2. Watts DD, Fakhry SM. Incidence of hollow viscus injury in blunt trauma: an analysis from 275,557 trauma admissions from the EAST Multi-Institutional Trial. *J Trauma* .2003;54(2):289-294.
3. Mourad M, Desrousseaux B, Atai I, Abizeid G, Lepoutre B, Ampe J. Delayed perforation of the sigmoid colon following closed abdominal trauma. Apropos of a case report. *Acta Chir Belg* 1992;92(4):172-175.
4. Bubenik O, Meakins JL, Mclean AP. Delayed perforation of the colon in blunt abdominal trauma. *Can J Surg* 1980;23(5):473-475.
5. erpell JW, Nicholls RJ. Stercoral perforation of the colon. *Br J Surg* 1990;77(12):1325-1329.
6. Cormio L, Perttilä I, Saarinen O, Tierala E, Nordling S, Ruutu M. Spontaneous perforation of rectum by carcinoma of the prostate. Case report. *Tumori* 1993;79(4):280-282.
7. Tokunaga Y, Hata K, Nishitai R, Kaganoi J, Nanbu H, Ohsumi K. Spontaneous perforation of the rectum with possible stercoral etiology: report of a case and review of the literature. *Surg Today* 1998;28(9):937-939.
8. Yamazaki T, Shirai Y, Tada T, Sasaki M, Sakai Y, Hatakeyama K. Ischemic colitis arising in watershed areas of the colonic blood supply: a report of two cases. *Surg Today* 1997;27(5):460-462.
9. Siddharth P, Ravo B. Colorectal neurovasculature and anal sphincter. *Surg Clin North Am*.1998 Dec;68(6):1185-1200.
10. GRIFFITHS JD. Surgical anatomy of the blood supply of the distal colon. *Ann R Coll Surg Engl* 1956;19(4):241-256.
11. Hughes TM, Elton C. The pathophysiology and management of bowel and mesenteric injuries due to blunt trauma. *Injury* 2002;33(4):295-302.
12. Esposito TJ, Ingraham A, Luchette FA, Sears BW, Santaniello JM, Davis KA, et al. Reasons to omit digital rectal exam in trauma patients: no fingers, no rectum, no useful additional information. *J Trauma* 2005;59(6):1314-1319.
13. Fakhry SM, Watts DD, Luchette FA. Current diagnostic approaches lack sensitivity in the diagnosis of perforated blunt small bowel injury: analysis from 275,557 trauma admissions from the EAST multi-institutional HVI trial. *J Trauma* 2003;54(2):295-306.
14. Killeen KL, Shanmuganathan K, Poletti PA, Cooper C, Mirvis SE. Helical computed tomography of bowel and mesenteric injuries. *J Trauma* 2001;51(1):26-36.
15. Glaser K, Tschmelitsch J, Klingler P, Wetscher G, Bodner E. Ultrasonography in the management of blunt abdominal and thoracic trauma. *Arch Surg* 1994;129(7):743-747.
16. Boulanger BR, McLellan BA, Brennehan FD, Wherrett L, Rizoli SB, Culhane J, et al. Emergent abdominal sonography as a screening test in a new diagnostic algorithm for blunt trauma. *J Trauma* 1996;40(6):867-874.
17. Buzzas GR, Kern SJ, Smith RS, Harrison PB, Helmer SD, Reed JA. A comparison of sonographic examinations for trauma performed by surgeons and radiologists. *J Trauma* 1998;44(4):604-608.
18. McStay C, Ringwelski A, Levy P, Legome E. Hollow viscus injury. *J Emerg Med* 2009; 37(3):293-299.