

Umbilical endometriosis associated with Umbilical Hernia

Mehrangiz Zamani Bonab¹, Shahla Nasrolahi², Nosrat Neghab³

SUMMARY

Abdominal wall endometriosis is defined as endometrial tissue superficial to the peritoneum. Cutaneous endometriosis is a well known but rare phenomenon. We present a case of spontaneous umbilical endometriosis.

KEY WORDS: endometriosis, umbilical nodule, umbilical endometriosis.

Pak J Med Sci April - June 2011 Vol. 27 No. 2 471-473

How to cite this article:

Bonab MZ, Nasrolahi S, Neghab N. Umbilical Endometriosis Associated with Umbilical Hernia. Pak J Med Sci 2011;27(2):471-473

INTRODUCTION

Umbilical endometriosis is a rare pathology of the umbilicus. The incidence of umbilical endometriosis is as high as 0.5% to 4%. Presenting symptoms include an umbilical lesion with a cyclic history of pain, swelling, itching and occasionally bloody discharge during menstruation. A bluish or brownish hue of nodule has been reported. Clinical diagnosis of this benign condition can be difficult even with the aid of cytology and imaging. Therefore, surgical excision with removal and histopathology is recommended for both diagnostic and therapeutic purposes. The treatment is complete surgical excision, as medical therapy is often incompletely effective. Recurrence is uncommon.^{1,2}

1. Mehrangiz Zamani Bonab, Assistant Professor,
 2. Shahla Nasrolahi, Assistant Professor,
 3. Nosrat Neghab, Resident,
- 1-3: Department of Obstetrics and Gynecology, Hamedan University of Medical Sciences, Hamedan, Iran

Correspondence:

Nosrat Neghab, MD,
Department of Obstetrics and Gynecology,
Hamedan University of Medical Sciences,
Hamedan, Iran.
E-mail: drneghab@yahoo.com

* Received for Publication: January 25, 2010

* Accepted: January 1, 2011

CASE REPORT

A 34 years old woman nulligravid infertile with unknown etiology presented with a one year history of slow growing, painful, violaceous nodule on the umbilicus that increased during her menstruation, with a chronic ulcer presentation. She had no history of previous surgery, or previous illnesses. There was no evidence of pelvic endometriosis on examination. She reported normal menstruation. Otherwise, the systemic review was unremarkable. She could not recall any specific changes to the mass or associated pain in relation to her menstrual cycle. In the physical exam there was soft, dome shaped, ulcerated, brown 10mm×6mm nodule not reducible or pulsatile and without an impulse on coughing. There was a small bleeding spot under the skin but without ulceration in the umbilicus. Surgical exploration revealed an umbilical hernia. The hernia defect was repaired, and the surgical specimen was sent to pathology for evaluation. Microscopic sections revealed sections of skin with an endometriotic focus within the lower dermis. There were cysts with dilated glands lined by columnar epithelium with surrounding stromal cells (Figures 1-4). The patient underwent a gynecologic and endocrinology evaluation, CA125 values is normal, and diagnostic laparoscopy for infertility was without any evidence of pelvic endometriosis.

DISCUSSION

The prevalence of pelvic-endometriosis has been reported to be as high as 44% in asymptomatic women

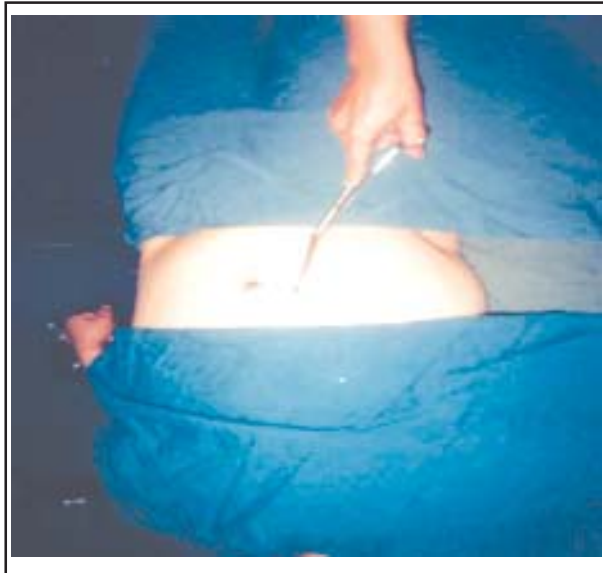

Fig-1: Dome shaped, ulcerated, brown 10mm×6mm nodule in umbilicus.

undergoing laparoscopy for non gynecological symptoms, while the incidence of umbilical endometriosis is estimated to be only 0.5% to 4% of all women with an extragonadal endometriosis.³ In our case, the patient presented with a bleeding umbilical hernia. Umbilical endometriosis occurs in women between 30 to 40 years of age. It is usually a solitary, firm, brownish or bluish nodule ranging from 0.5 to 3 cm in size. Approximately 1% of women with endometriosis has a nodule of umbilical endometriosis. The

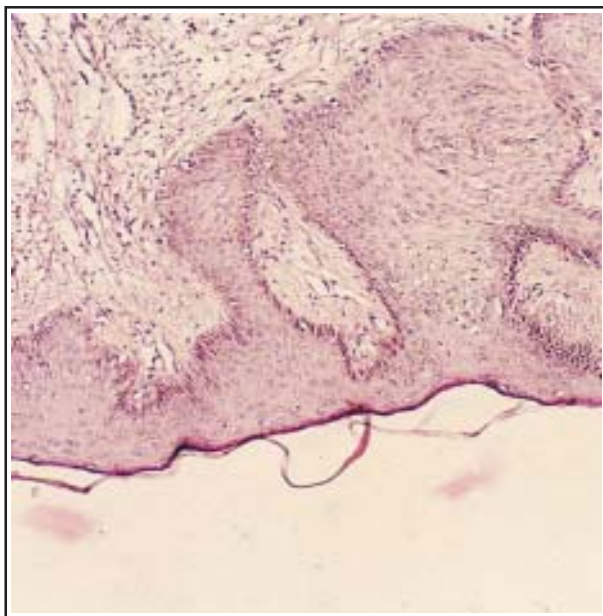


Fig-3: Histological section reveals typical endometrial stroma enclosing glandular lamina lined by columnar epithelial cell

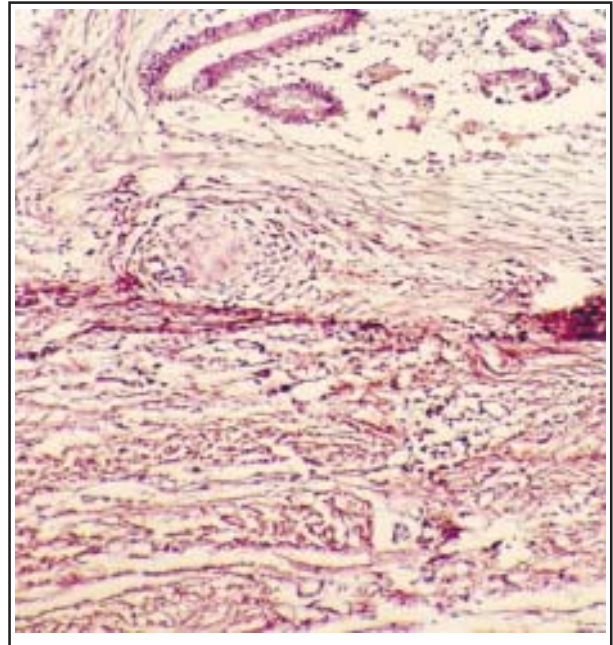


Fig-2: Microscopic sections revealed sections of skin with an endometriotic focus within the lower dermis

mechanism of formation of umbilical endometriosis appears to be unknown, although, there are two major theories: metastasis and metaplasia. Umbilical endometriosis may arise by lymphatic or hematogenous dissemination, or by metaplasia, or possibly by a combination of the two. The differential diagnosis of umbilical nodules includes: embryological rests, irreducible umbilical hernia, pyogenic granuloma, primary malignancy such as malignant

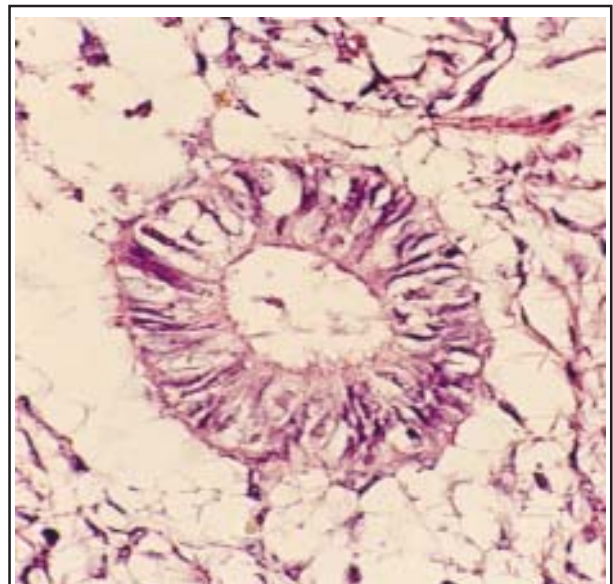


Fig-4: Endometrial gland with glandular lamina lined by columnar epithelial cell.

endometriosis in the umbilicus, or secondary metastatic tumour from an intra-abdominal malignancy. Surgical excision is necessary for proper histopathological diagnosis that will dictate the plan of management.³

A series of 82 cases of cutaneous endometriosis indicates that scar tissue is particularly susceptible to endometrial implantation.¹ Abdominal wall endometriosis is usually associated with incisional abdominal scars and occurs most commonly following a Cesarean section. It has been suggested that the umbilicus acts as a physiologic scar with a predisposition for developing endometriosis. Umbilical endometriosis has been well described in the literature, occurring either spontaneously or following laparoscopic procedures in which a trocar was placed through the umbilicus.⁴

Although a medical treatment can be considered, the treatment of choice in these patients should be excisional surgery so as to avoid lesion relapse and the risk of oncogenic transformation.⁵ As our case illustrates, some patients may perceive no correlation between their symptoms and menstrual cycle. The diagnosis is often made incidentally by histologic examination of the specimen.^{5,6}

CONCLUSION

In rare incidences, endometriosis can present a diagnostic challenge to the general surgeon evaluating an umbilical hernia rarely. Our patient presented

with a one year history of umbilical mass for one year. She reported no correlation between her pain and menses and was initially thought to have an incarcerated hernia with possible bowel strangulation. Histologic examination of the surgical specimen revealed endometriosis adjacent to the hernia sac. This case highlights the importance of considering endometriosis in the differential diagnosis of any woman who presents with umbilical swelling and pain, regardless of whether the pain correlates with her menses.

REFERENCES

1. Teh WT, Vollenhoven B, Harris PI. Umbilical endometriosis, a pathology that a gynecologist may encounter when inserting the Veres needle. *Fertil Steril* 2006;86:1764.e1-2.
2. Schachter L, Tash J, Olgac S, Bochner BH. Umbilical Endometriosis. *J Urol*. 2003;170(6):2388-2389.
3. Seleem MI, Hashemy A, Obeid MA. Umbilical Endometriosis: A Diagnostic Dilemma. *Kuwait Med J*. 2002;34(4):303-305.
4. Steck WD, Helwig EB. Cutaneous endometriosis. *Clin Obstet Gynecol*. 1966;9(2):373-383.
5. Fedele L, Frontino G, Borruto BF, Bianchi S, Ciappina N. Umbilical endometriosis: A radical excision with laparoscopic assistance. *Int J Surg*. 2010;8(2):109-11.
6. Horton JD, DeZee KJ, Ahnfeldt EP, Wagner M. Abdominal wall endometriosis: a surgeon's perspective and review of 445 cases. *Am J Surg*. 2008;196:207-212.