



Sonographic Features Predictive of Thyroid Nodule Malignancy in a Nigerian Population

**Owoyomi Oluwatoyin Rebecca^{1*}, Asaleye Christianah Mopelola¹
and Komolafe Akinwumi Oluwole²**

¹Department of Radiology, Obafemi Awolowo University Teaching Hospitals Complex, Ile-Ife, Nigeria.

²Department of Morbid Anatomy and Forensic Medicine, Obafemi Awolowo University Teaching Hospitals Complex, Ile-Ife, Nigeria.

Authors' contributions

This work was carried out in collaboration between all authors. Author OOR designed the study, performed the statistical analysis, wrote the protocol, and wrote the first draft of the manuscript. Author ACM provided the guidance and supervision for the successful completion of the research, read and approved of the initial documentations. Author KAO is the pathologist in charge of the evaluation of the cytology and histology slides for cellular diagnoses of the lesions and he also read the manuscript. All authors read and approved the final manuscript.

Article Information

DOI: 10.9734/JAMMR/2018/v28i1230041

Editor(s):

- (1) Dr. Mohammed Osman, Consultant, General Organization of Teaching Hospitals and Institutes, Cairo, Egypt.
(2) Dr. Muhammad Toreql Islam, Nuclear of Pharmaceutical Technology (NTF), Federal University of Piauí, Brazil.

Reviewers:

- (1) Mahrukh Kamran, Dow University of Health and Sciences, Pakistan.
(2) Abinaya R. Nadarajan, Christian Medical College and Hospital, Vellore, Tamilnadu, India.
Complete Peer review History: <http://www.sdiarticle3.com/review-history/46984>

Original Research Article

Received 28 October 2018

Accepted 15 February 2019

Published 04 March 2019

ABSTRACT

Aims: To determine the ultrasound malignancy score (UMS) and identify the ultrasound (US) features of thyroid nodule (TN) associated with malignancy, in our study population, using fine-needle aspiration cytology (FNAC) as the gold standard.

Study Design: A prospective observational study.

Place and Duration of Study: Departments of Radiology and Morbid Anatomy and Forensic Medicine, Obafemi Awolowo University Teaching Hospital Complex, Ile Ife, Nigeria, between June 2016 and May 2017.

Methodology: We studied 110 thyroid nodules in 110 adult subjects (97males and 13males). Neck ultrasound scan (USS) to evaluate and score 7 sonographic features of the nodules for their

*Corresponding author: E-mail: oowoyomi@gmail.com;

malignant potential as well as simultaneous Ultrasound Guided Fine Needle Aspiration (USG-FNAC) was done. The findings were compared and data was analyzed using Statistical Package for Social Science (SPSS) version 20.

Results: USG-FNAC findings showed that of the 110 thyroid nodules studied, 107(97.3%) were benign while 3(2.7%) were malignant. Receiver operating characteristic curve showed that at sensitivity and specificity of 66.7% and 88.8% respectively giving UMS of 4.5. All the 3 nodules that were malignant on USG-FNAC had micro calcification and irregular margins on ultrasound ($p=0.05$).

Conclusion: Using USG-FNAC as the gold standard, thyroid nodules with UMS of 4.5 are likely to be malignant. Ill-defined margins and micro calcifications on ultrasound are suggestive of malignancy in thyroid nodules.

Keywords: Thyroid nodules; malignancy; ultrasound; USG - FNAC.

1. INTRODUCTION

Nodules within the thyroid gland are common and they are mostly benign [1,2]. Nevertheless each nodule has to be accurately identified as benign or malignant [3,4]. High resolution Ultrasound (USS) is the most sensitive and globally accepted imaging modality for the initial evaluation of thyroid nodules (TN). USS is non-invasive, widely available, less expensive and it does not use ionizing radiation [4]. However the usefulness of USS in the evaluation of TN is often limited due to the considerable overlap between the sonographic features of benign and malignant TN [3]. For this reason fine needle aspiration for cytology (FNAC) has become a popular procedure in differentiating between benign and malignant TN.

FNAC is considered the method of choice to diagnose thyroid cancer though it is invasive and more expensive [4]. Given the high prevalence of TN, and the resources required, performing FNAC for every TN discovered will be prohibitive [5]. FNAC is further limited by the possibility of inadequate sampling. The development of accurate and reliable USS based criteria to predict malignancy will reduce the need for FNAC [6]. For this reason some studies have proposed ultrasound based TN malignancy score as a tool for risk classification such that only the TN that is suspicious for malignancy will be subjected to FNAC [4,6].

An ultrasound based tool for risk classification is essential in resource-poor environments, especially in places where most healthcare financing is out of the individual patient's financial capability such as ours. To be effective this tool has to be simple reliable and easily reproducible [4]. To the best of our knowledge such a tool is yet to be developed among Nigerians with TN.

Therefore the aim of this study is to determine the Ultrasound Malignancy Score (derived from seven sonographic features of TN) and identify the USS features of TN that are associated with malignancy in our study population using FNAC as the gold standard.

2. MATERIALS AND METHODS

This is a prospective observational study carried out at the Radiology and Morbid Anatomy departments of a tertiary hospital in South West Nigeria following approval by the institutional Ethical and Research committee.

We consecutively selected and studied 110 consenting adults aged 18 to 80 years referred for ultrasound evaluation of thyroid nodules. Subjects with non-nodular goitre, those on thyroid therapy and those who did not consent were excluded from the study.

The research project was explained to each patient and a written consent was obtained. Demographic data, family history of thyroid disease and history of head and neck irradiation in childhood were recorded.

Ultrasound examinations were performed with Mindray DC-7 (Shenzhen, China) using a linear transducer probe with frequency of 7-12 MHz. In patients with multiple nodules the nodule with sonographic features most suggestive of malignancy was chosen as the index nodule. B-mode and Doppler ultrasound was performed to evaluate the following features on the nodule: echogenicity, calcification, shape, size, internal content, margin and vascularity.

The ultrasound features were recorded and graded as shown in Table 1 [7].

All ultrasound examinations were performed by a senior registrar in Radiology and a consultant Radiologist. Immediately after USS evaluation of the thyroid, FNAC was performed. A 23-25 gauge needle attached to a 5ml syringe was introduced into the thyroid nodule with real time ultrasound monitoring of the needle tip. The aspirated sample was placed on a glass slide, smeared and fixed in 95% alcohol by the consultant Pathologist who also read and interpreted the slides according to the Bethesda system for reporting thyroid cytopathology.

The sonographic features of the thyroid nodules and other characteristics of each subject were recorded in a proforma. These were entered into the Excel spread sheet and transferred to Statistical Package for Social Science (SPSS) version 20 for analysis. The USS findings for each patient were categorized and scored as done in below study [14] (Table 1).

Socio-demographic, clinical and sonographic findings of study subjects were presented as relative frequencies. Bivariate analysis was carried out to compare ultrasound findings and USG-FNAC in differentiating benign from malignant thyroid nodules. Chi-square and corresponding *p* values were used to compare categorical variables. Using USG-FNAC as the standard, Receiver operating characteristic curve (ROCC) was used to determine a cut-off point for making a diagnosis of benign or malignant nodule with the malignant nodule score. The sensitivity, specificity and predictive values of the diagnostic outcome of ultrasound in differentiating benign and malignant thyroid

nodules were also calculated. *P* value of < .05 was regarded as statistically significant.

2.1 Description of Sonographic Features

2.1.1 Hypo-echoic

The same or reduced echogenicity compared with strap muscles.

2.1.2 Hyper-echoic

Nodule more echogenic than thyroid parenchyma OR same echogenicity as thyroid parenchyma.

2.1.3 Micro-calcification

Small hyperechoic punctate foci (<1mm) without posterior acoustic shadows.

2.1.4 Macro-calcification

Coarse and large foci >1mm with posterior acoustic shadows.

2.1.5 Taller than wide

When the anteroposterior diameter of the nodule is longer than its transverse diameter on a transverse or longitudinal plane.

2.1.6 Wider than tall

When the anteroposterior diameter of the nodule is shorter than its transverse diameter on both transverse and longitudinal planes.

Table 1. A table showing various ultrasound findings of thyroid nodule and the scores

Ultrasound features	Ultrasound findings	Score
Echogenicity	Hypoechoic	1
	Hyperechoic/Isoechoic	0
Calcification	Micro calcification	1
	Macro calcification	0
Shape	Taller than wider	1
	Wider than taller	0
Size	≥10mm	1
	<10mm	0
Internal content	Solid	1
	Cystic/Spongiform	0
Margin	Ill-defined	1
	Smooth	0
Vascularity	Markedly Intra-nodular vascularity	1
	Markedly Peri-nodular vascularity	0

1: Features suggestive of malignancy; 0: Features suggestive of benignity

Table 2. Demographic characteristics of subjects with thyroid nodules

Variables	Freq	%
Age group(years)		
<31	14	12.7
31-40	25	22.7
41-50	21	19.1
51-60	30	27.3
>60	20	18.2
Sex		
Female	97	88.2
Male	13	11.8
Family history of neck swelling		
No	92	83.6
Yes	18	16.4
Neck X-Ray		
No	109	99.1
Yes	1	0.9
Duration of neck swelling(Years)		
<1	11	10
1 -4	42	38.2
5-10	20	18.2
>11	12	10.9
Not known	25	22.7

2.1.7 Size

Measures $\geq 10\text{mm}$ on any plane or measures $< 10\text{mm}$. Solid: Liquid portion less than 10% of nodule volume.

2.1.8 Cystic spongiform

Liquid portion $\geq 50\%$ but $\leq 90\%$ of the nodule containing clustered microcystic space separated by echogenic septa.

2.1.9 Ill-defined

No clear demarcation of nodule from normal thyroid parenchyma.

2.1.10 Smooth

There is a clear demarcation from normal thyroid parenchyma.

2.1.11 Intra-nodular vascularity

Flow predominantly within the nodule.

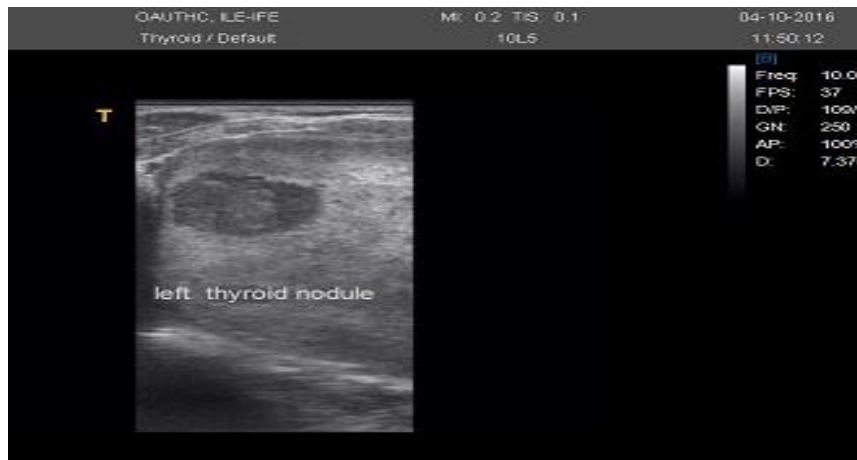

Fig. 1. Longitudinal plane B mode ultrasound scan of the thyroid gland showing an oval shaped, smoothly margined, wider than tall hypoechoic nodule

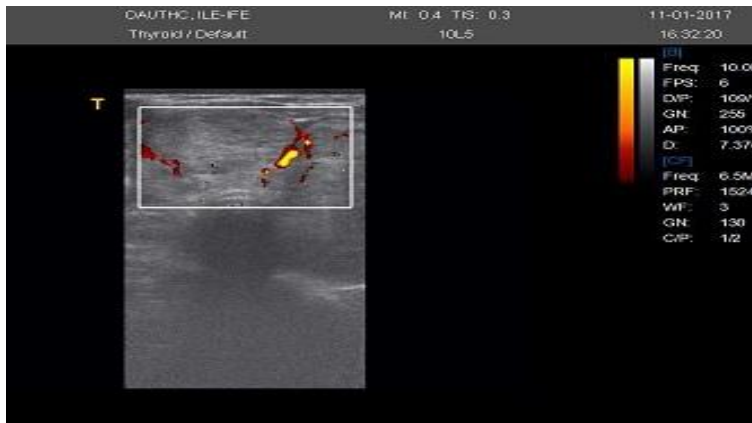

Fig. 2. Transverse plane B mode and colour Doppler USS showing a smoothly margined, wider than tall, isoechoic, predominantly solid nodule with perinodular vascularity

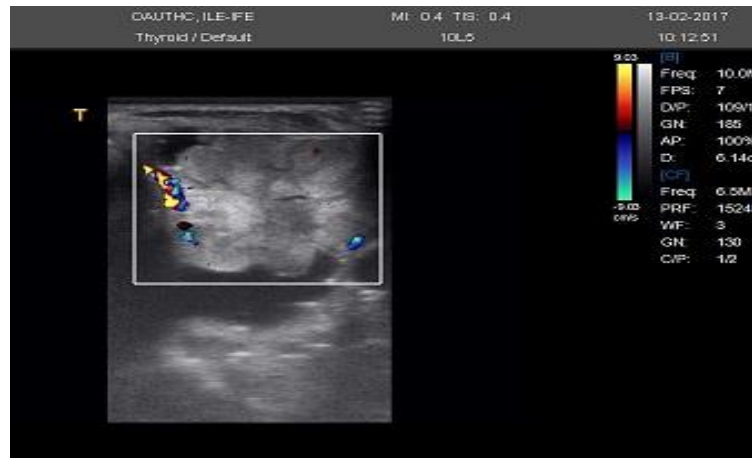

Fig. 3. Transverse plane, B mode and colour Doppler USS showing an ill-defined, irregularly margined, taller than wide, predominantly solid hyperechoic nodule with perinodular vascularity

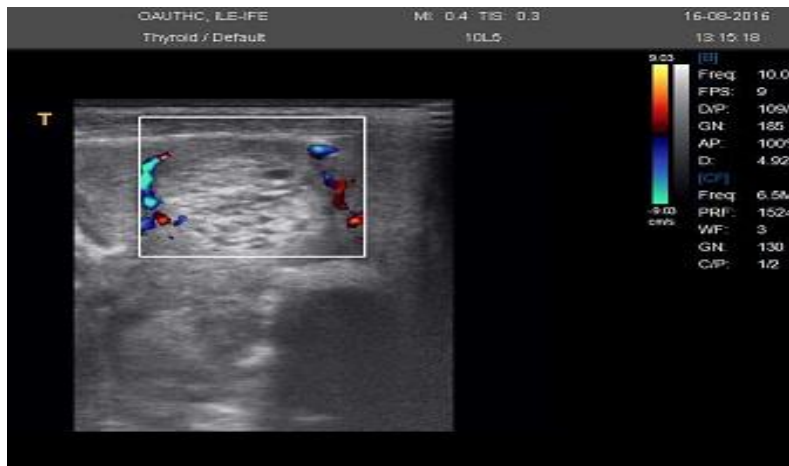

Fig. 4. Transverse plane, B mode and colour Doppler USS showing a smoothly margined wider than tall hyperechoic, spongiform nodule with perinodular vascularity

2.1.12 Peri-nodular vascularity

Flow predominantly in the periphery of the nodule.

3. RESULTS

3.1 Demographic Characteristics of the Study Population

We performed USG-FNA of 110 thyroid nodules on 110 subjects comprising of 97(88.2%) females and 13(11.8%) males. Their age range is between 18 and 80 years with a mean of 48.3±15years. Most of the subjects with thyroid nodules in this study are between ages 51 – 60 years also most of them presented within 1-4years of having the goitre.

3.2 Ultrasound Findings in Thyroid Nodules

The ultrasonographic features of the thyroid nodules of patients with nodular thyroid goitre are shown in Figs. 1 – 4.

The thyroid nodules with ill-defined margins were 29.1% while 70.9% had smooth margins; 42.7% were hypoechoic while the rest were hyperechoic; 44.5% had micro-calcification while the rest had macro-calcification; 25.5% had markedly intra-nodular vascularity while the rest had markedly peri-nodular vascularity. Most of the thyroid nodules (85.5%) had sizes ≥10mm while the rest were ≤10mm suggesting benignity; 74.5% of the thyroid nodules were solid while the rest were cystic; and, only a few of the nodules (8.2%) were taller than wide in shape while the rest were wider than taller (Fig. 5).

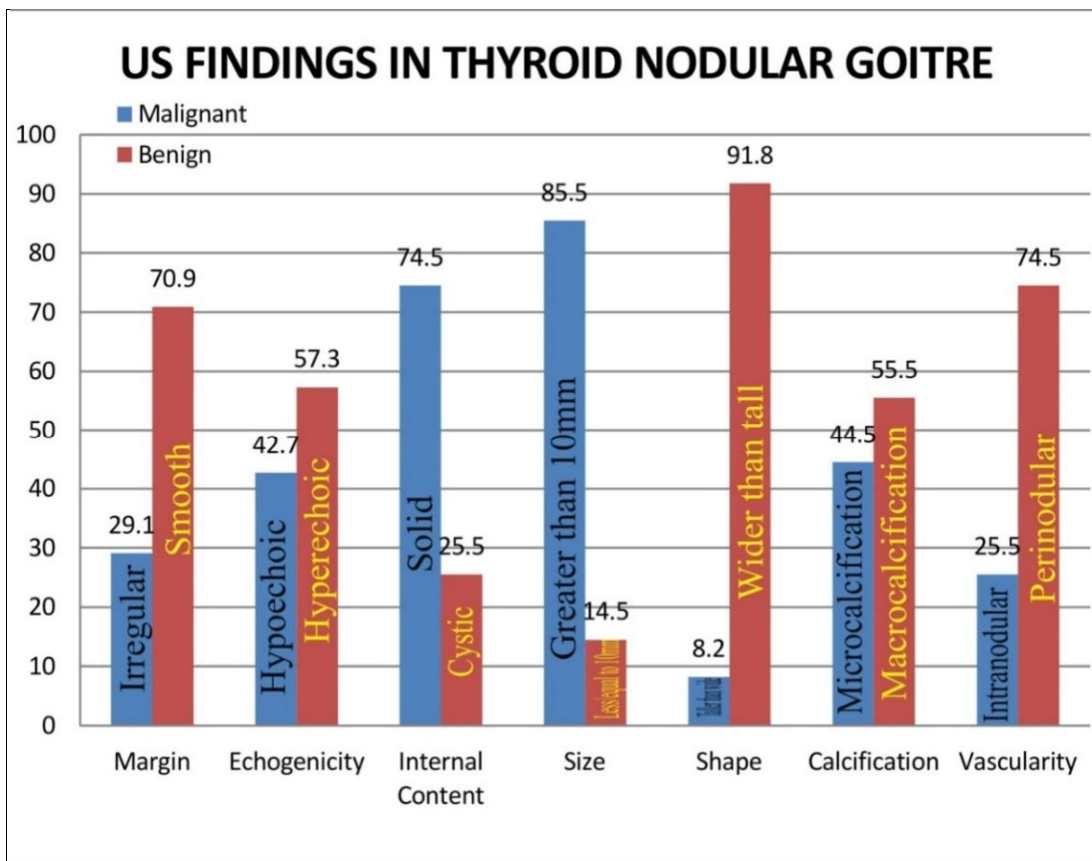


Fig. 5. Bar chart showing frequency of specific B mode and colour Doppler ultrasonography findings that suggest benignity and malignancy in patients with thyroid nodules

Table 3. Association between demographic characteristics and ultrasound guided fine-needle aspiration cytology findings in thyroid nodules

Variables	USGFNAC				P value
	Benign		Malignant		
	Freq	%	Freq	%	
Age group					
<31 years	14	100.0	0	0.0	.443
31-40 years	25	100.0	0	0.0	
41-50 years	20	95.2	1	4.8	
51-60 years	28	93.3	2	6.7	
>60 years	20	100.0	0	0.0	
Family history of neck swelling					
No	89	96.7	3	3.3	.437
Yes	18	100.0	0	0.0	
Total	107	97.3	3	2.7	
Sex					
Female	96	99.0	1	1.0	.003
Male	11	84.6	2	15.4	
History of neck x- ray					
No	106	97.2	3	2.8	.866
Yes	1	100.0	0	0.0	
Duration of neck swelling					
<1 years	11	100.0	0	0.0	.733
1 -4 years	40	95.2	2	4.8	
5-10 years	20	100.0	0	0.0	
>11 years	12	100.0	0	0.0	
Don't know	24	96.0	1	4.0	

Table 4. Comparison of B mode and colour Doppler ultrasound findings with ultrasound guided fine-needle aspiration cytology findings in thyroid nodules

Ultrasound Features	USGFNAC				p value
	Benign		Malignant		
	Freq	%	Freq	%	
Margin					
Smooth	78	72.9	0	0	.006
Ill- defined	29	27.1	3	100	
Echogenicity					
Hyperechoic	62	57.9	1	33.3	.40
Hypoechoic	45	42.1	2	66.7	
Internal Content					
Cystic	27	25.2	1	33.3	.75
Solid	80	74.8	2	66.7	
Size					
>10mm	16	15	3	0	.47
≤10mm	91	85	0	100	
Shape					
Wider than tall	98	91.6	3	100	.60
Taller than wide	9	8.4	0	0	
Calcification					
Macro-calcification	61	57	0	0	.05
Micro-calcification	46	43	3	100	
Vascularity					
Perinodular	81	75.7	1	33.3	.10
Intra-nodular	26	24.3	2	66.7	

Table 5. Comparison of USG-FNAC and UMS

		USG-FNAC Findings		Total
		Benign	Malignant	
US malignancy score	Benign (<4.5)	95(TN) (88.8%)	1(FN) (33.3%)	96
	Malignant (≥4.5)	12(FP) (11.2%)	2(TP) (66.7%)	14
Total		107 (100%)	3 (100%)	110

Table 6. Comparing diagnostic accuracy assessment of UMS / other sonographic parameters with USG-FNAC (Gold standard)

Variables	Sensitivity (%)	Specificity (%)	NPV (%)	PPV (%)	Accuracy (%)
USS malignancy score	88.8	66.7	98.9	14.3	88.2
Margin	100.0	72.9	100.0	9.4	73.6
Micro calcification	100.0	57.0	100.0	6.1	58.1
Hypoechoic	66.7	57.9	98.4	4.3	58.2
Solid internal content	66.7	25.2	96.4	2.4	26.4
Size >10mm	100.0	15.0	100.0	3.2	26.4
Shape (wider than tall)	0.0	90.7	97.0	0.0	89.1
Intranodular Vascularity	66.7	75.7	98.8	7.1	57.3

NPV- Negative predictive value; PPV- Positive predictive value

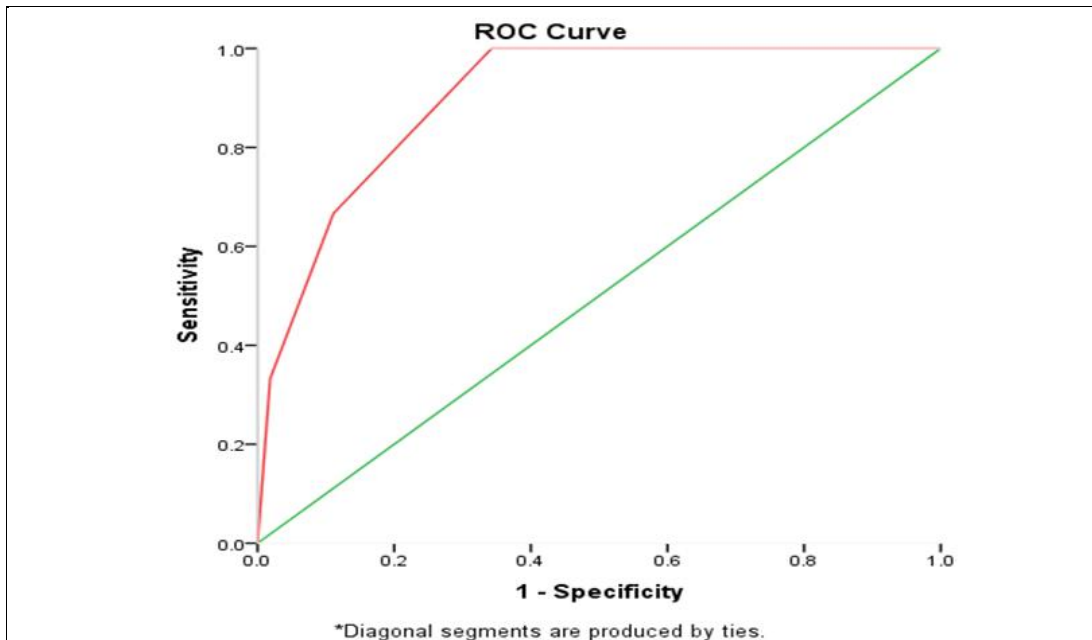


Fig. 6. Receiver Operating Characteristic Curve (ROCC) of malignancy score

3.3 Association between Demographic Characteristics and USG-FNAC Findings in Thyroid Nodules

There is a statistical significance between sex and USG-FNAC findings ($p = .003$). No statistical significance was found between the other demographic characteristics and USG-FNAC findings.

3.4 Comparison of B mode and Doppler Sonographic Findings with USG-FNAC Findings

Concordance was noted between the sonographic features and USG-FNAC findings in those thyroid nodules that had ill-defined margins ($p = .006$) and those that had micro-calcifications ($p = .05$). All other sonographic features were discordant with the USG-FNAC findings as shown on (Table 4).

3.5 Comparison of Ultrasound Malignancy Score (UMS) with USG-FNAC Findings

Results as presented in Table 5, showed that 11.2% of the nodules with malignant UMS had benign USG-FNAC findings while 33.3% of the nodules with benign UMS were malignant on USG-FNAC.

3.6 Comparing Diagnostic Accuracy Assessment of UMS / other Sonographic Parameters with USG-FNAC (Gold Standard)

For each sonographic features suggestive of malignancy, calculated diagnostic performance including sensitivity, specificity, positive predictive value (PPV), negative predictive value (NPV) and accuracy are listed in Table 6. Margin and micro calcification had the highest PPV (9.4 and 6.1).

3.7 Receiver Operating Characteristic Curve (ROCC) to Assess the Nature of Thyroid Nodules Using Ultrasonography

The best combination of sensitivity and specificity in thi study is 66.7% and 88.8% respectively from ROCC which is at a cut-off point of malignancy score of 4.5.

4. DISCUSSION

This study was conducted on 110 adults with thyroid nodules.

We found a higher prevalence of goitre in females (88%) amongst our studied patients which is in keeping with the fact that thyroid nodules is prevalent in females [5]. About 27% of the patient that presented with thyroid nodules are within the age range 51-60years. Similarly Hamid et al. [8] found an increased frequency of goitre in women over 45 years of age.

In our study 2.7% of patients had malignant thyroid nodules. This is less than the prevalence found in a hospital based study similar to this one by Lawal et al. [9] (12.9%) 16 years ago in the same hospital. Although the larger sample size in their study may account for the difference in prevalence, our findings may suggest a decrease in malignant thyroid nodules in this locality. A larger community based study is required to validate this finding. Edino et al. [10] in North-western Nigeria found a prevalence of 15.0% of malignant thyroid disease which is higher than ours and those of Lawal et al. [9] done in South-western Nigeria. Differences in environmental factors between regions in Nigeria may account for this difference. Lannucillii et al. [11] found a prevalence of 5.33% in their study in 70 English patients while Wienke et al. [12] found a prevalence of 2.9% in a population of 70 Americans. The lower prevalence in the study of Lannucilli et al. [11] and Wienke et al. [12] compared to ours and that of Lawal et al. [9] could be due to differences in genetic factors, environmental and consumption of goitrogenic materials that have been linked to thyroid nodules.

Malignant thyroid nodules were more prevalent in males (66.7%) than females (33.3%) in this study. This is however contrary to the study by Edino et al. [10] who found a higher prevalence of malignant thyroid nodules among females (72%) than males (28%) .Reza ,Lisa and Kebebew [13] also found in their study that thyroid cancer is 2-9 times more common in females than males in contrary to our own finding. The larger number of malignant nodules presented in the study by Edino et al. [10] (25 patients) compared to ours (3 patients) is probably due to the large number of cases studied by the authors spanning a period of 7 years. Environmental factors may also be responsible for this difference in findings.

Our finding however tallies with those of Wienke et al. [12] who found an even higher prevalence of 100% of their 2 patients with FNAC confirmed malignant thyroid nodules in males. Hence, a study with a larger sample size is recommended to validate this finding.

The three malignant thyroid nodules (confirmed on USG-FNAC) in this study had micro-calcifications (100%) and this finding was statistically significant ($p=0.005$). This implies that micro-calcifications within a thyroid nodule is a strong indicator that such a nodule could be malignant. Similarly, Alper et al. [14] observed that 42.9% of the 35 malignant nodules studied had micro-calcifications and this finding was statistically significant ($p<0.0001$). Chan et al. [15] noticed that 47% of 55 malignant nodules in their study had micro-calcifications. The differences in prevalence noticed in these two studies and our study may be due to differences in the sample size and genetic variation in the studied patients.

Two (66.7%) out of the three USG-FNAC confirmed malignant thyroid nodules in this study had ill - defined margins ($p=0.006$). Chan et al. [15] similarly found that 53% of the 29 malignant nodules in their study had ill-defined margins. Kim et al similarly found that 49.1% of the 59 malignant nodules in their study had ill-defined margins and this was statistically significant ($p<0.01$). Despite the differences in genetic make-up of Patients in our study and that of Kim et al. [16], both study showed statistical significance for malignant nodules with ill-defined margins. Our study showed that the prevalence of hypoechogenicity in FNAC confirmed benign and malignant thyroid nodules are 42.1% and 66.7% respectively. Hence, hypoechogenicity occurred more in malignant thyroid nodules in this study. This finding was not however statistically significant ($p = 0.395$). This is similar to the findings of Lannucillii et al. [11] who found 30.6% of benign nodules and 47.1% of malignant nodules in their study to be hypoechoic which was also not statistically significant. Papini et al. [17] similarly found 55% of benign nodules and 87% malignant nodules in their study were hypoechoic. Despite ethno-racial differences and differences in genetic composition of patients in our study and the other aforementioned studies higher prevalence of hypoechogenicity was demonstrated in malignant thyroid nodules.

In this study, hyperechogenicity was found in 57.9% and 33.1% of the FNAC confirmed benign

and malignant nodules respectively. Hence, hyperechogenicity occurred more in benign nodules although this finding was not statistically significant. Similarly, Lannucillii et al. [11] did not find statistical significance between prevalence of benign and malignant nodules with hyperechogenicity. Despite similar findings, the prevalence of hyperechogenicity in our study is higher than that of the study by Lannucillii et al. [11]. Again, genetic variation could account for the differences in the prevalence of this USS feature between the 2 studies.

All the three malignant thyroid nodules in this study had sizes greater than 10mm on ultrasound. Again, this finding was not of statistical significance. Similarly, Papini et al [17] who found that there is a slightly higher prevalence of cancer in nodules >10mm in diameter compared with those <10mm did not find statistical significance. Cappelli et al. [18] on the other hand found statistically significant higher prevalence of malignancy in nodules > 10mm in size in their study ($p < 0.001$). This may be due to the larger number of study Patients with malignant thyroid nodules in their study (284 Patients) compared to ours (3 Patients) and that of Papini et al. [17] (31 Patients).

We found that 66.7% and 74.8% of the FNAC confirmed malignant and benign nodules respectively had solid internal contents on ultrasound. This is contrary to the study by Lannucillii et al. [11] in Brazil who found a slightly higher prevalence of solid internal contents in the malignant nodules compared to benign nodules among 85.3% and 83.3% respectively. In like manner, a study conducted by Peccini et al. [19] among Americans found a much higher prevalence of solid internal contents in malignant thyroid nodules compared to benign nodules (68.8% and 46.9% respectively). The slight difference in the findings of these two studies and this index study may be attributed to ethno-racial differences, genetic factors and possibly environmental factors even though the findings were not statistically significant in the studies.

Cystic internal contents was seen in 33.3% of the malignant thyroid nodules in our study. This finding was not statistically significant ($p=0.751$). Chan et al. [15] and Lee at al. [20] quoted lower percentages than that of our study (13% and ≈5%). This may imply that cystic internal contents may be a pointer that the nodule is not malignant. However further studies should be carried out.

All the three malignant nodules (100%) in this study were wider than tall. This finding was not however statistically significant ($p=0.6$). Moon et al. [20] found that out of 360 malignant thyroid nodules they studied, 57.8% had a wider than tall shape. Lannucillii et al. [11] also found that 45.9% of 34 malignant nodules in their study were wider than taller in shape which was also not statistically significant ($p =0.240$). We can therefore postulate that a wider than tall nodule could be a malignant thyroid nodule particularly in this environment.

In our study perinodular vascularity on Doppler interrogation was demonstrated more in benign nodules compared to malignant nodules (75.7% and 33.3% respectively). This finding was however not statistically significant ($p = 0.097$). Alper et al. [14] similarly found there is a higher prevalence of perinodular vascularity among benign nodules in their study when compared to the malignant nodules (25.8% and 17.1%) although again this finding was not statistically significant ($p>0.05$). The higher percentages noticed in our study and theirs despite similar findings may be due to difference in sample volume.

33.3% and 66.7% of the malignant thyroid nodules demonstrated both perinodular and intra-nodular vascularity respectively on Doppler interrogation. It can be deduced from this study that about two thirds of malignant thyroid nodules will demonstrate intra-nodular flow pattern although a perinodular vascular flow pattern is also seen in malignant thyroid nodules. This finding was not however statistically significant ($p=0.097$). In the study by Alper et al. [14] 17.1% and 60% of malignant nodules in their study demonstrated perinodular and intra-nodular vascularity respectively. This finding was however not statistically significant ($p>0.005$). We can therefore conclude from our study no vascular pattern is specific for benign or malignant thyroid nodules this is in keeping with the findings Rosario et al. [21] and Algin et al. [22].

A score of 1 was given to any of the 7 malignant USS features when present while 0 was given when absent. The sum of these scores indicate the ultrasound malignancy score (UMS) for each subject. The minimum possible score being 0 indicates no USS features suggestive of malignancy while the maximum possible score being 7 indicates that the 7 USS features were suggestive of malignancy.

A Receiver operating characteristic Curve (ROCC) was constructed with ultrasound malignancy score (UMS). The plot yielded a combination of specificities and sensitivities at different cut-off points of the UMS.

The best combination of sensitivity and specificity in this study is 66.7% and 88.8% respectively which gives a cut- off of malignancy score 4.5. Therefore a patient with more than four ultrasound scan features suggestive of malignancy by the UMS is likely to have malignancy with a sensitivity of 66.7% and a specificity of 88.8%. Unsal et al. [7] reported a malignancy score of 3 in their studied cohort with a sensitivity and specificity of 51.7% and 96.7% respectively. The lower score reported is presumably due to the lower number of thyroid nodule sonographic indices used (5 vs. 7 indices in the index study).

A positive predictive value, negative predictive value and accuracy of 14.3%, 98.9% and 88.2% respectively for UMS was found in this study. On the other hand, Unsal et al. [7] reported positive predictive value, negative predictive value and accuracy of 88.2%, 80.6% and 80.2% respectively for their UMS. The lower positive predictive value in the index study is presumably due to high false positive values obtained which further supports the need to compare USS features with histology (as seen in the Unsal et al. [7] study) rather than with cytology.

Despite an UMS (ultrasound malignancy score) of 4.5 in this study, a sub-analysis of the 3 malignant nodules confirmed by cytology shows that one of these patients had an UMS of 4 (false negative) which is less than the score required for classification as malignancy. However the 2 USS features which showed statistical significance viz a viz ill-defined margins and micro-calcification were present in this subject. There is possibility that USM score could have lower than 4.5 with final histology reports rather than the cytology reports used in this study. The cytology reports of our patients could not be confirmed by histology which supersedes it as many of them are yet to undergo surgery. A further analysis of our patients with histology reports when available is therefore recommended.

Furthermore, a subgroup analysis of the 12 USS diagnosed malignant nodules which turned out to be benign at cytology (False positives) showed that 11 (91.7%) of them had one or both of the 2 significant features (ill-defined margin or micro-

calcification) and an USM score above 4.5.this further supports the need to further compare USS features with histology rather than cytology which is superior in tissue diagnosis.

The limitations of this study include the fact that it is hospital based which may imply a selection bias since only patients who presented in the teaching hospital setting were recruited for the study. In addition cytology, rather than histology which is more sensitive for tissue diagnosis, was used as a gold standard in this study.

5. CONCLUSION

Our findings suggest that on high resolution USS, thyroid nodules with ill-defined margins, microcalcification and those nodules with more than 4 of the 7 sonographic features suggesting malignancy considered in this study may be treated as malignant. We recommend that such thyroid nodules should be subjected to definitive tissue diagnosis. Furthermore a larger community based study preferably using histopathology rather than cytological correlation will further evaluate the potential of ultrasound in the evaluation of malignant thyroid nodules among in our population.

CONSENT

All authors declare that 'written informed consent was obtained from the patient.

ETHICAL APPROVAL

This is a prospective observational study carried out at the Radiology and Morbid Anatomy departments of a tertiary hospital in South West Nigeria following approval by the institutional Ethical and Research committee.

COMPETING INTERESTS

Authors have declared that no competing interests exist.

REFERENCES

1. Olusola-Bello M, Agunloye A, Adeyinka A. Ultrasound prevalence and characteristics of incidental thyroid lesions in Nigerian adults. *African Journal of Medicine and Medical Sciences*. 2013;42(2):125-130. PMID: 24377197
2. McQueen AS, Bhatia KS. Thyroid nodule ultrasound: Technical advances and future horizons. *Insights into imaging*. 2015;6(2):173-188. DOI:10.1007/s13244-015-0398-9; PMID: 25736837
3. Hoang JK, Lee WK, Lee M, Johnson D, Farrell S. US Features of thyroid malignancy: Pearls and pitfalls 1. *Radiographics*. 2007;27(3):847-860. DOI:10.1148/rg.273065038; PMID: 17495296
4. Pompili GG, Tresoldi S, Ravelli A, Primolevo A, Di Leo G, Carrafiello G. Use of the ultrasound-based total malignancy score in the management of thyroid nodules. *Ultrasonography*. 2018;37(4):315. DOI:10.14366/usg.17063
5. Syrenicz A, Koziółek M, Ciechanowicz A, Sieradzka A, Bińczak-Kuleta A, Parczewski M. New insights into the diagnosis of nodular goiter. *Thyroid Res*. 2014;7. DOI:10.1186/1756-6614-7-6; PMID: 24987460
6. Kim D, Park J, In H, Choo H, Ryu J, Jung S. Ultrasound-based diagnostic classification for solid and partially cystic thyroid nodules. *American Journal of Neuroradiology*; 2012. DOI:10.3174/ajnr.A2923; PMID: 22300928
7. Unsal O, Akpınar M, Turk B, et al. Sonographic scoring of solid thyroid nodules: effects of nodule size and suspicious cervical lymph node. *Brazilian Journal of Otorhinolaryngology*; 2016. DOI: 10.1016/j.bjorl.2016.01.013.; PMID: 27161187
8. Hamid E. Assessment of Goitre in Patients in Omdurman Central Military Hospital Using Ultrasoundgraphy, Sudan University of Science and Technology; 2016.
9. Lawal O, Agbakwuru A, Olayinka O, Adelusola K. Thyroid malignancy in endemic nodular goitres: Prevalence, pattern and treatment. *European Journal of Surgical Oncology (EJSO)*. 2001;27(2): 157-161. DOI:10.1053/ejso.2000.1085; PMID: 11289751
10. Edino S, Mohammed A, Ochicha O, Malami S, Yakubu A. Thyroid cancers in nodular goiters in Kano, Nigeria. *Nigerian Journal of Clinical Practice*. 2010;13(3).
11. Iannuccilli JD, Cronan JJ, Monchik JM. Risk for malignancy of thyroid nodules as assessed by sonographic criteria the need for biopsy. *Journal of Ultrasound in Medicine*. 2004;23(11):1455-1464.

- DOI:10.7863/jum.2004.23.11.1455; PMID: 15498910
12. Wienke JR, Chong WK, Fielding JR, Zou KH, Mittelstaedt CA. Sonographic features of benign thyroid nodules interobserver reliability and overlap with malignancy. *Journal of Ultrasound in Medicine*. 2003;22(10):1027-1031. DOI:10.7863/jum.2003.22.10.1027; PMID: 14606557
 13. Rahbari R, Zhang L, Kebebew E. Thyroid cancer gender disparity. *Future Oncology*. 2010;6(11):1771-1779. DOI:10.2217/fon.10.127; PMID: 21142662
 14. Ozel A, Erturk SM, Ercan A, et al. The diagnostic efficiency of ultrasound in characterization for thyroid nodules: how many criteria are required to predict malignancy? *Medical Ultrasonography*. 2012;14(1):24-28. PMID: 22396935
 15. Chan BK, Desser TS, McDougall IR, Weigel RJ, Jeffrey RB. Common and uncommon sonographic features of papillary thyroid carcinoma. *Journal of Ultrasound in Medicine*. 2003;22(10):1083-1090. DOI:10.7863/jum.2003.22.10.1083; PMID: 14606565
 16. Kim BM, Kim MJ, Kim E-K, et al. Sonographic differentiation of thyroid nodules with eggshell calcifications. *Journal of Ultrasound in Medicine*. 2008;27(10):1425-1430. DOI:10.7863/jum.2008.27.10.1425; PMID: 18809952
 17. Papini E, Guglielmi R, Bianchini A, et al. Risk of malignancy in nonpalpable thyroid nodules: predictive value of ultrasound and color-Doppler features. *The Journal of Clinical Endocrinology & Metabolism*. 2002;87(5):1941-1946. DOI:10.1210/jcem.87.5.8504; PMID: 11994321
 18. Cappelli C, Castellano M, Pirola I, et al. The predictive value of ultrasound findings in the management of thyroid nodules. *Qjm*. 2007;100(1):29-35. DOI:10.1093/qjmed/hcl121; PMID: 17178736
 19. Peccin S, De Castro J, Furlanetto TW, Furtado A, Brasil B, Czepielewski M. Ultrasonography: is it useful in the diagnosis of cancer in thyroid nodules? *Journal of endocrinological investigation*. 2002;25(1):39-43. DOI:10.1007/BF03343959
 20. Lee M-J, Kim E-K, Kwak JY, Kim MJ. Partially cystic thyroid nodules on ultrasound: probability of malignancy and sonographic differentiation. *Thyroid*. 2009; 19(4):341-346. DOI:10.1089/thy.2008.0250; PMID: 19355824
 21. Rosario PW, Silva ALd, Borges MAR, Calsolari MR. Is Doppler ultrasound of additional value to gray-scale ultrasound in differentiating malignant and benign thyroid nodules? *Archives of Endocrinology and Metabolism*. 2015;59(1):79-83. DOI:10.1590/2359-3997000000014; PMID: 25926119
 22. Algin O, Algin E, Gokalp G, et al. Role of duplex power Doppler ultrasound in differentiation between malignant and benign thyroid nodules. *Korean Journal of Radiology*. 2010;11(6):594-602. DOI:10.3348/kjr.2010.11.6.594; PMID: 21076584

© 2018 Rebecca et al.; This is an Open Access article distributed under the terms of the Creative Commons Attribution License (<http://creativecommons.org/licenses/by/4.0>), which permits unrestricted use, distribution, and reproduction in any medium, provided the original work is properly cited.

Peer-review history:
The peer review history for this paper can be accessed here:
<http://www.sdiarticle3.com/review-history/46984>