



# **Preliminary Study of the Possible Benefit of the Reversible Acetylcholinesterase Inhibitor Donepezil for Cognitive Impairment Associated with Corticosteroid Treatment for Presumptive Neurosarcoidosis with a Lesion in the Right Basal Ganglia and Thalamus**

Laurie Jo Moore<sup>1\*</sup>, Mila Goldner- Vukov<sup>2,3</sup>, Rachel Huso<sup>1</sup>, Risa Ishino<sup>1</sup>  
and Samuel Althausen<sup>1</sup>

<sup>1</sup>Loma Linda University, Loma Linda VA, Loma Linda, CA, USA.

<sup>2</sup>Belgrade University, Serbia.

<sup>3</sup>James Cook University, Cairns, Australia.

## **Authors' contributions**

*This work was carried out in collaboration between all authors. Author LJM treated the patient, designed the study, completed the initial literature search and wrote the all drafts of the manuscript. Author MGV provided consultation in the treatment and preparation of the paper and manuscript. Author RH completed a revised literature review and helped submit the documents. Author RI completed a literature review of the psychopharmacology literature and completed all documents required for publication by the Veterans Administration and author SA assisted in preparing the case presentation. All authors read and approved the final manuscript.*

## **Article Information**

DOI: 10.9734/BJMMR/2017/33821

### Editor(s):

(1) Mohammed Rachidi, Molecular Genetics of Human Diseases, French Polynesia, University Paris 7 Denis Diderot, Paris, France.

### Reviewers:

(1) Alicia García Falgueras, The Official College of Psychologists, Madrid, Spain.  
(2) Luca Gallelli, University of Catanzaro, Mater Domini University Hospital, Italy.  
(3) Jorge A. Herrera Pino, Herbert Wertheim College of Medicine, Florida International University, Florida, USA.  
Complete Peer review History: <http://www.sciencedomain.org/review-history/19377>

**Case Study**

**Received 30<sup>th</sup> April 2017**  
**Accepted 29<sup>th</sup> May 2017**  
**Published 6<sup>th</sup> June 2017**

## **ABSTRACT**

**Aims:** To present the case of a patient diagnosed by neurology with neurosarcoidosis with cognitive impairment after long-term treatment with corticosteroids who showed marked improvement in his cognition upon initiation of donepezil. To provide a brief overview of the

\*Corresponding author: E-mail: laurie.moore2@va.gov, lauriejo.moore.ljm@gmail.com;

treatment of neurosarcoidosis and corticosteroid-induced cognitive disorders with acetylcholinesterase inhibitors and clarify any literature regarding the use of acetylcholinesterase inhibitors in neurosarcoidosis.

**Presentation of Case:** G.A. was a 46-year-old African American veteran who spent 14 years in the Army as a Patriot Missile Crewmember. He was exposed to active combat and ionizing radiation in the gulf and suffered from Posttraumatic Stress Disorder (PTSD) and Recurrent Major Depressive Disorder Moderate (MDD). Eight years after retirement he presented with transient visual symptoms and left-sided focal facial and lower extremity weakness. Neurosarcoidosis was diagnosed by his neurologist who identified a lesion in his right basal ganglia and thalamus on MRI. He was treated with corticosteroids for 8-9 years and referred for psychiatric evaluation 1 year after cessation of corticosteroids. He reported persisting slowed thinking, impaired memory and slow reaction times. Neuropsychological testing done 1 year after diagnosis was repeated 3 years later and showed little change. He had been treated with sertraline 200 mg daily for PTSD and MDD. Donepezil 5 mg at bedtime was added and after 2 months he reported marked improvement. Donepezil was increased to 10 mg and after 1 week his thinking returned to normal and he had no complaints. His wife confirmed his history. He was thinking more clearly; his recall and reaction time were improved and he felt more confident in himself. Follow-up neuropsychological testing is planned in 12 months.

**Discussion:** There are no reports of the use of acetylcholinesterase inhibitors in the treatment of neurosarcoidosis.

**Conclusion:** The use of donepezil for the treatment of corticosteroid-induced cognitive impairment in neurosarcoidosis deserves further investigation.

*Keywords: Neurosarcoidosis; steroid-induced cognitive impairment; donepezil.*

## 1. INTRODUCTION

The senior authors treated several patients with corticosteroid-induced delirium. One patient with Polymyalgia Rheumatica and Bipolar Disorder had corticosteroid-induced delirium for more than 6 months and did not improve until corticosteroids were discontinued. Another patient with longstanding corticosteroid-induced delirium due to treatment for Minimal Change Disease responded rapidly to treatment with donepezil. (Unpublished data) These experiences led the treating clinician to consider the use of donepezil in the patient in this report who had cognitive impairment after 8-9 years of corticosteroid treatment.

## 2. PRESENTATION OF THE CASE

G.A. was a 46 y/o African-American male who had been married for 23 years and lived with his wife and 2 children. He served in the US Army for 14 years as a Patriot Missile Crewmember where he was exposed to ionizing radiation. He was involved in active combat. About a year after his discharge he was diagnosed with PTSD and MDD. He sustained a rupture of his right femoral artery due to contact injury that required surgery and an artificial artery in his leg along with chronic anticoagulation therapy.

Six years after discharge he began to experience episodes of transient blurred vision but did not

seek any medical care. Three years later he had a 3-4-day episode of left facial droop with sparing of the forehead, left leg weakness, and frontal headaches in addition to blurred vision. He presented to the hospital for the first time after this episode and was diagnosed with neurosarcoidosis by a neurologist who identified a lesion on MRI. MRI with and without contrast demonstrated a 4 cm x 3.6 cm x 3.5 cm lobular mass in the right basal ganglia extending into the right thalamus and right aspect of the midbrain and pons. (See Initial MRI) A mass effect was noted with a 4 mm right to left midline shift at the septum pellucidum. The patient had no cognitive deficits at that time. Oral dexamethasone 10 mg was given every 6 hours to start and decreased to 6 mg every 6 hours at the time of discharge. Treatment was switched to prednisone. Nine months after starting corticosteroids his depression intensified and he reported anhedonia and feelings of worthlessness. He was disturbed by a weight gain of over 100 pounds. Within a year of taking corticosteroids he developed impaired cognition. Neuropsychological testing done after these symptoms failed to resolve showed impaired performance in processing speed, visuospatial skills, learning and memory and abstract nonverbal reasoning. The neuropsychologist felt his cognitive impairment was due to his corticosteroid treatment. Repeat neuropsychological testing 3 years later

showed no significant change. He remained on maintenance treatment for the next 8 years until the mass in his right ganglia had reduced to about the size of a quarter. (See Latest MRI) Corticosteroids were stopped and one year later he was referred for a psychiatric evaluation.

On psychiatric review, he reported long-standing difficulties with short-term recall, slow processing speed, and difficulty remembering daily tasks. His wife managed their finances; he was unable to drive and required a caregiver to dispense medications. He was administered a brief screening measure to evaluate mild cognitive impairment, the Montreal Cognitive Assessment (MoCA). He scored 29/30 which is within the normal range. However, because of his rather severe functional impairment and the results of his previous neuropsychological testing, donepezil 5 mg at bedtime was started. Two months later he reported significant improvement and after 2 weeks of 10 mg at bedtime he reported he was feeling great, his confidence had improved and he had no complaints. His thinking, recall and reaction times were all normal. His wife confirmed his report. He reported this medicine completely changed his life. In the authors' experience, this kind of response to donepezil has always been maintained. He will require ongoing evaluation and repeat neuropsychological testing to thoroughly evaluate his progress.

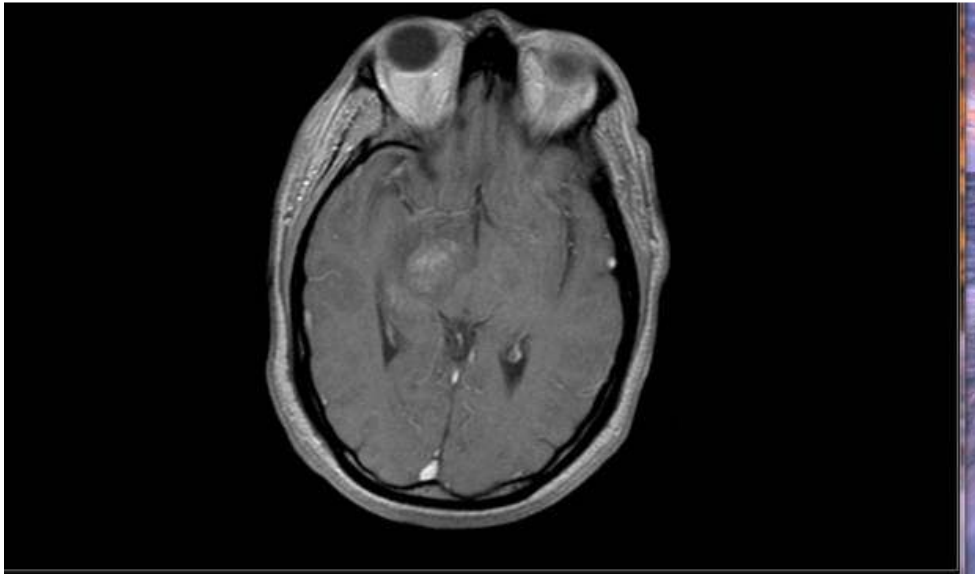
### 3. DISCUSSION

A myriad of medical disorders have been treated with corticosteroids. The psychiatric consequences of corticosteroid treatment have been well-established. They vary with the corticosteroid used, the route of administration, the dose, the patient's underlying genetic polymorphism and to some degree the duration of treatment or the number of episodes of treatment. Psychiatric symptoms are likely to appear early in the treatment course by day 1-5 or week 1-4. Once symptoms are manifest they do not tend to intensify to any significant degree over extended periods. The following psychiatric conditions are reported with the frequencies reported in different studies: depression in 23.6-40.5%, mania in 27.80-54%, mixed episodes in 7.6-12%, delirium in 10-20%, and psychosis in 11-61%. Mania appears to present more commonly early in treatment and depression after prolonged therapy. Symptoms present within 3-5 days in 39%, within one week in 60%

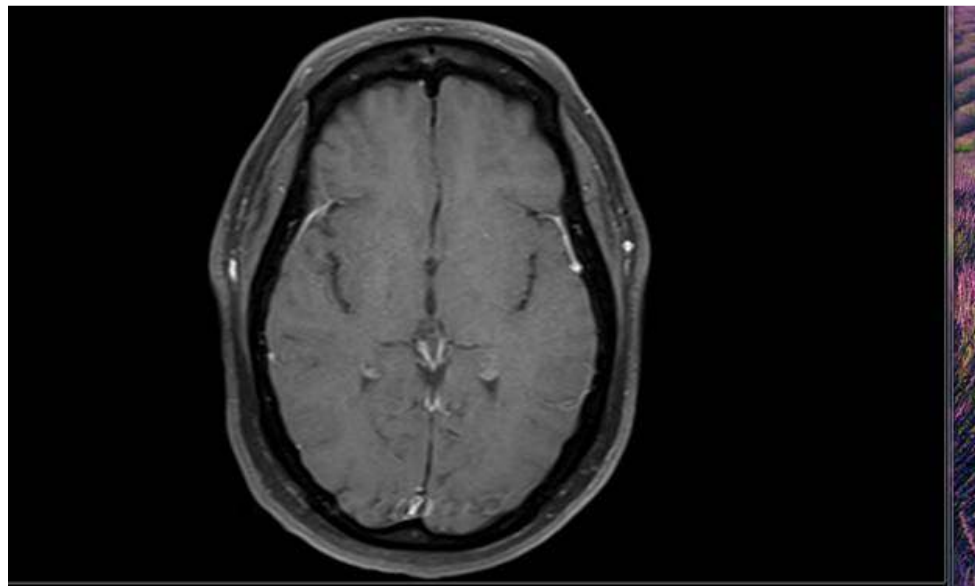
and 62% within 2 weeks. The greater the dose of prednisone, the greater the risk of psychosis with a frequency of 3% at 30 mg and 8% at 90 mg. Dementia which has sometimes been reversible is usually associated with doses greater than 90 mg. Although people may show psychiatric disorders with one course of corticosteroids, it may not recur with subsequent courses. The average time to onset of hypomania or mania at a dose of 44.8 +/- 45.6 mg was 14 +/- 16.7 days, the onset for depression at a dose of 73.2 +/- 48.4 was 12/4 +/-10.2 days, the onset for delirium at a dose of 62.2 +/-45mg was 7 +/- 9.3 days, and psychosis usually presents within 2 weeks. Cognitive effects appear to be dose-related and are reversible with discontinuation in 94% of patients. No specific medication therapies for cognitive impairment related to corticosteroid therapy have been reported in humans [1,2,3,4].

Neurosarcoidosis is a relatively rare disorder for which there is no known cure and no accepted guidelines for treatment. It is of note that the Veterans Administration recognizes sarcoidosis as a service-connected disorder after exposure to ionizing radiation. Sarcoidosis can affect many parts of the body, especially the lungs and in a small number of patients when it involves some part of the nervous system is it called "neurosarcoidosis". The presentation of this patient with sudden facial weakness is common and it can affect any of the cranial nerves as well as the spinal cord and areas affecting body temperature, sleep and stress responses. It can lead to symptoms of any space-occupying lesion depending on where it is in the brain and affect sensation or motor activity as well as causing delirium and dementia. Long-term therapy is often required for neurosarcoidosis but spontaneous remission has occurred. Immunosuppression with corticosteroids is the cornerstone of therapy which alleviates severe and progressive symptoms in about 50% of patients. The prognosis for peripheral neuropathy is better than with central nervous system involvement. In refractory cases, other immunosuppressive agents have been used including cyclosporine, methotrexate, azathioprine, chloroquine and cyclophosphamide and the use intravenous immunoglobulin has been reported. Low-dose radiation has been used in some cases of brain involvement [5,6].

The fact that the visual symptoms and focal paresis associated with an abnormal MRI resolved with corticosteroid therapy and did not



**Fig. 1. Initial MRI**



**Fig. 2. Latest MRI**

recur suggest that the treatment of his neurosarcoidosis was effective in alleviating his symptoms and halting the progression of this disorder. Repeat MRI's also showed a resolution of the mid-line shift and progressive shrinking of the mass in his right ganglia. (See most recent MRI).

Donepezil is a reversible inhibitor of acetylcholinesterase with the US Food and Drug Administration (FDA) approved indication for the

treatment of mild-moderate and severe Alzheimer's disease. It exerts its therapeutic effects by increasing the concentration of acetylcholine and enhancing cholinergic function [7]. There are case reports of patients treated with donepezil for corticosteroid-induced cognitive impairment in patients with multiple sclerosis, cancer patients with brain tumors surviving radiation, patients with neurosyphilis and patients with Down's syndrome. A full discussion of these studies is beyond the scope

of this paper. It is important to realize, however, that donepezil has been used outside the parameters established by the FDA that restrict its use to the treatment of Alzheimer's Disease [8-13].

There are no reports in the literature of the use of acetylcholinesterase inhibitors for the treatment of corticosteroid-induced cognitive impairment in neurosarcoidosis.

The cognitive impairments in this patient presented after several years of corticosteroid treatment. These symptoms could possibly be attributed to his neurosarcoidosis but according to his treating neurologists they felt his illness was well-controlled because of the resolution of all his focal neurological symptoms and the reduction in size of his brain lesion. In addition, the neuropsychologist was of the opinion that his symptoms were due to his corticosteroids. Cessation of the corticosteroids for one year did not result in any progression of his neurosarcoidosis but there was no resolution of his cognitive impairment. As the above discussions suggest, 94% of psychiatric disorders resolve upon discontinuation of corticosteroids. There have been cases of corticosteroid-induced dementia and also reversible dementia reported. The pathophysiology of his cognitive impaired cannot be determined in any definitive manner because we do not possess the technology to answer this question. It appears most likely that he has suffered from a persisting delirium or a dementia as a consequence of prolonged corticosteroid therapy.

The authors were surprised that there was no literature on the use of acetylcholinesterase inhibitors in the treatment of corticosteroid-induced cognitive impairment in neurosarcoidosis. It is possible that the lack of efficacy found on the Cochrane Review for the use of acetylcholinesterase inhibitors in delirium has negatively influenced their use for other cases of cognitive impairment [14].

#### 4. CONCLUSION

The extensive differential diagnosis in delirium and the undoubtedly varied etiological pathophysiology which remains largely unknown should encourage clinicians to investigate the use of acetylcholinesterase inhibitors in cases of cognitive impairment of undetermined etiology. We recommend that further research be done on

the use of donepezil in the treatment of corticosteroid-induced cognitive impairment in neurosarcoidosis.

#### CONSENT

As per international standard or university standard written patient consent has been collected and preserved by the authors.

#### ETHICAL APPROVAL

It is not applicable.

#### COMPETING INTERESTS

Authors have declared that no competing interests exist.

#### REFERENCES

1. Circaco M, Ventrice P, Russo G, Scicchitano M, Maxxitello G, Scicchitano F, Russo E. Corticosteroid-related central nervous system side effects. *J Pharmacol Pharmacother.* 2013;4(Suppl 1):S94-S98.
2. Kenna HA, Poon AW, de los Angeles C, Koran LM. *Psychiatry and Clinical Neurosciences.* 2011;65:549-560.
3. Brown ES, Chandler PA. *Primary Care Companion J Clin Psychiatry.* 2001;3(1): 17-21.
4. Brown ES, Vera E, Frol AB, Woolston DJ, Johnson B. Effects of chronic prednisone therapy on mood and memory. *J Affect Disord.* 2007;99(1-3):279-283.
5. Bucurescu G, Ramachandran TS. Neurosarcoidosis treatment and management. *Medscape.* 2016;1-10. (Accessed 4/25/2017) Available:[http://emedicine.medscape.com/article/1147324-treatment?scrpoc\\_goodle\\_rsla\\_ref\\_kw...](http://emedicine.medscape.com/article/1147324-treatment?scrpoc_goodle_rsla_ref_kw...)
6. Scott TF, Yandora K, Valeri A, Chieffe C, Schramke C. Aggressive therapy for neurosarcoidosis: Long-term follow-up of 48 treated patients. *Arch Neurol.* 2007; 64(5):691-6.
7. US Food and Drug Administration Aricept Package Insert.
8. Attia A, Page BR, Lesser GJ, Chan M. Treatment of radiation-induced cognitive decline. *Current Treatment Options in Oncology.* 2015;15:539-550.
9. Christodoulou C, MacAllister WS, McLinskey NA, Krupp LB. Treatment of

- cognitive impairment in multiple sclerosis. Is the use of acetylcholinesterase inhibitors a viable option? *CNS Drugs*. 2008;22(2): 87-97.
10. Davis J, Ahlberg FM, Berk M, Ashley DM, Khasraw M. Emerging pharmacotherapy for cancer patients with cognitive dysfunction. *BMC Neurology*. 2013;13: 153-161
  11. Wu Y, Lane H, and Lin C. Donepezil improved cognitive deficits in a patient with neurosyphilis. *Clin Neuropharm*. 2015;38: 156-157.
  12. Kondoh T, Kanno A, Itoh H, Nakashima M, Honda R, Kojima M, et al. Donepezil significantly improves in daily lives of female Down Syndrome patients with severe cognitive impairment: A 24-week randomized, double-blind, placebo-controlled trial. *Int'l J. Psychiatry in Medicine*. 2011;41(1):71-89.
  13. Rapp SR, Case LD, Peiffer A, Naughton MM, Chan MD, Stieber VW, et al. Donepezil for irradiated brain tumor survivors: A phase III randomized placebo-controlled clinical trial. *J Clin Oncol*. 2015; 33:1653-1659.
  14. Overshoot R, Karim S, Burns A. Cholinesterase inhibitors for delirium (Review). *The Cochrane Collaboration: The Cochrane Library Issue I*; 2008.

© 2017 Moore et al.; This is an Open Access article distributed under the terms of the Creative Commons Attribution License (<http://creativecommons.org/licenses/by/4.0>), which permits unrestricted use, distribution, and reproduction in any medium, provided the original work is properly cited.

*Peer-review history:*  
*The peer review history for this paper can be accessed here:*  
<http://sciencedomain.org/review-history/19377>