

## Safety and technical success of percutaneous left main coronary artery stenting

Liaqat Ali<sup>1</sup>, Shahid Nawaz Malik<sup>2</sup>, Abdullah Bin Khalid<sup>3</sup>,  
Mehboob Sultan<sup>4</sup>, Nadeem Sadiq<sup>5</sup>

### ABSTRACT

**Objective:** Critical stenosis of left main coronary artery (LMCA) has always remained a challenge for interventional cardiologists. Conventionally Coronary Artery Bypass Grafting (CABG) is done for these patients but recently Percutaneous Coronary Intervention (PCI) is also being tried more frequently, but data of PCI is scarce in this regard. Our objective was to determine the safety and technical success rate of percutaneous left main coronary artery stenting.

**Methods:** This was 12 month follow up study conducted at Pakistan Institute of Medical Sciences (PIMS), Islamabad from 11<sup>th</sup> Jan 2012 to 11<sup>th</sup> Jan 2013. All symptomatic patients who underwent coronary angiogram at PIMS and were found to have either isolated LMCA disease or coexisting ostial Left Anterior Descending (LAD) artery disease were potentially eligible for the study. Patients who had previous surgical treatment for coronary artery disease and those with renal dysfunction requiring dialysis were excluded. Patients were counselled in detail regarding the pros and cons of PCI versus CABG. Those who opted for PCI were included in the study. All these patients were treated with percutaneous left main coronary artery stenting with or without ostial LAD stenting.

**Results:** Seventy two patients had LMCA disease during angiogram. Fifteen patients opted for CABG. Four patients did not meet the inclusion criteria, whereas 53 patients were finally enrolled. Mean age of patients were 55.45±10.275 years. Twenty nine patients were with acute coronary syndrome and 22 presented with unstable angina. PCI with stenting was technically successful in all patients. One patient died three months after PCI, there was no other mortality.

**Conclusion:** Our study showed that Percutaneous Coronary Intervention (PCI) to LMS has good technical success rate; the safety of the procedure is also acceptable.

**KEY WORDS:** Left main coronary artery, Coronary artery bypass graft.

doi: <http://dx.doi.org/10.12669/pjms.304.4859>

### How to cite this:

Ali L, Malik SN, Khalid AB, Sultan M, Sadiq N. Safety and technical success of percutaneous left main coronary artery stenting. *Pak J Med Sci* 2014;30(4):735-738. doi: <http://dx.doi.org/10.12669/pjms.304.4859>

This is an Open Access article distributed under the terms of the Creative Commons Attribution License (<http://creativecommons.org/licenses/by/3.0>), which permits unrestricted use, distribution, and reproduction in any medium, provided the original work is properly cited.

### INTRODUCTION

Significant left main coronary artery (LMCA) disease has been found in 3% to 5% of all patients who undergo coronary angiography and in 10%

to 30% of patients who undergo bypass surgery.<sup>1-4</sup> Critical LMCA stenosis puts patients at high risk of cardiovascular events because of the extent of jeopardized myocardium and associated multi-vessel coronary artery disease and, therefore, it has been considered as the most important coronary lesion in terms of prognosis. Current practice guidelines suggest coronary artery bypass grafting (CABG) as the standard procedure for patients with unprotected LMCA disease<sup>5-7</sup> primarily because long-term outcomes of surgical revascularization are superior to those of medical treatment.<sup>8-10</sup> However, because of anatomic accessibility and other characteristics, percutaneous coronary

#### Correspondence:

Liaqat Ali, FCPS (Medicine),  
Department of Cardiology,  
Pakistan Institute of Medical Sciences (PIMS), Islamabad, Pakistan.  
E-mail: [dr\\_liaqatali2@yahoo.com](mailto:dr_liaqatali2@yahoo.com)

- \* Received for Publication: December 20, 2013
- \* 1<sup>st</sup> Revision Received: January 7, 2014
- \* 2<sup>nd</sup> Revision Received: April 17, 2014
- \* Final Revision Accepted: May 12, 2014

intervention (PCI) for LMCA disease was attractive to the interventional cardiologist, and data from several archives showed its feasibility and short and midterm effectiveness. Nevertheless, PCI for LMCA disease has been limited to surgically high-risk patients and those with protected LMCA disease, or has been used as bailout procedures in patients with angioplasty complications.

Nonetheless, current improvements in interventional techniques and adjunctive pharmacology have challenged the orthodox wisdom that significant LMCA stenosis<sup>11-13</sup> should be cured surgically. The introduction of coronary stenting has led to a reassessment of the role of PCI as a practical treatment option for LMCA disease,<sup>14-17</sup> and the widespread availability of drug-eluting stents (DES), together with enhanced stenting techniques, has lowered the threshold for use of PCI, instead of CABG, in patients with LMCA disease.<sup>18</sup> The clinical experience with PCI for LMCA disease involves a wide spectrum of clinical and angiographic sub-categories of such patients. However, there has been little evaluation of the long-term safety and efficiency of PCI with stenting for LMCA disease, and no randomized trial has compared the two primary interventions (PCI versus CABG) in a large population.<sup>19</sup> We have therefore reviewed recent advances and the current status of percutaneous versus surgical treatment for LMCA disease, focusing on whether PCI is an alternative to or a possible replacement for CABG in these patients.<sup>20</sup>

The rationale of the study was to recognize the success rate of percutaneous left main coronary artery along with determination of safety till 12 months of follow-up.

## METHODS

**Inclusion/Exclusion Criteria:** All patients with age less than 70 years and having a history of coronary heart disease were included in the study. Whereas all patients who had previous surgical treatment for coronary artery disease, extreme left-dominant coronary artery perfusion, significant carotid stenosis requiring treatment and renal dysfunction requiring dialysis were excluded.

**Data Collection Procedure:** All patients who have history of coronary artery disease or who presented with acute coronary syndrome and were found to have either isolated LMCA disease or Osteal LAD disease along with LMCA were potentially eligible for enrollment. Patients were counselled in detail regarding pros and cons of PCI versus CABG. High risk informed consent was taken from those

who opted for PCI and were subsequently enrolled in the study. All procedures were performed by a single operator who has extensive experience of interventional cardiology. Angiogram was performed in Cardiac Catheterization laboratory at PIMS. All these patients were treated with PCI along with DES. In all patients everolimus drug eluting stents were used. Post stenting all patients were kept in Coronary Care unit (CCU) where their hemodynamics along with continuous ECG monitoring was done. All patients were started on dual antiplatelet therapy namely Aspirin and Clopidogrel. Those patients who had history of acute coronary syndrome were also treated with the antiplatelet agent Tirofiban. If patients remained stable for 24 hours they were moved to cardiology ward and discharged later on. All patients were followed up in cardiology outpatient Department fortnightly for the first two months and then monthly for the next 12 months.

**Statistical analysis:** Data was recorded on predesigned proforma and analyzed on SPSS version 17.0. Mean and standard deviation was calculated for quantitative variables whereas frequency and percentages were calculated for qualitative variables.

## RESULTS

Seventy two patients had LMS disease during angiogram, out of which 15 patients opted for CABG, 4 patients did not meet the inclusion criteria and thus 53 patients were finally enrolled (Fig.1). Patients were aged 35 – 68 years with mean age of  $55.45 \pm 10.275$  respectively. Male patients were 40

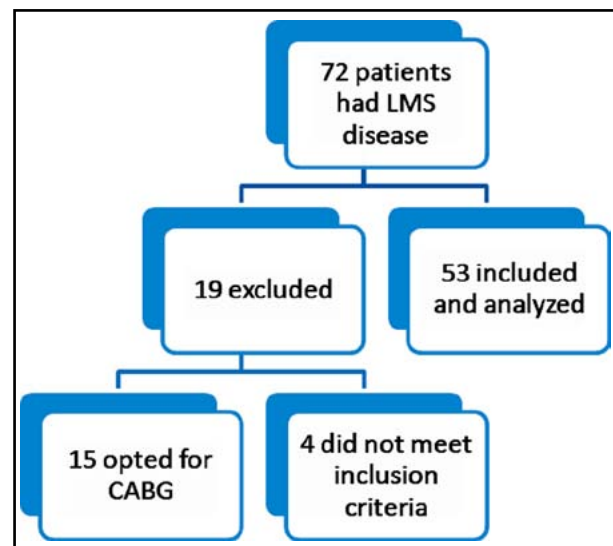


Fig.1: Study flow chart.

Table-I: Demographics of the study subjects.

Age (Years)	55.45±10.275
Male/Female	40/13
Acute coronary syndrome	29(52.8%)
Unstable Angina	22(41.5%)
Stable angina	2(3.7%)

(75.47%) and female patients were 13 (24.52%) in number. Twenty nine (52.8%) patients presented with acute coronary syndrome and 22 (41.5%) patients presented with unstable angina (Table-I). On coronary angiograms 45(84.9%) patients had LMCA stenosis along with Osteal LAD stenosis while the rest had isolated LMCA disease, out of these 45 patients 22 (41.5%) had ostial left main coronary artery disease, 13 (24.5%) had distal and 10 (18.8%) had mid LMS. Out of the 5 patients who developed Ventricular Tachycardia during PCI were successfully reverted to sinus rhythm by cardioversion. PCI with stenting was technically successful in all patients. On follow up at one month none of the patients had any symptoms of coronary artery disease. Their ECG did not show any new change. At 3<sup>rd</sup> month one of the patient who was a 45 year old male who had undergone a coronary stenting three months back due to an acute coronary syndrome (STEMI) presented to the Emergency department with acute chest pain. His ECG showed ST elevation in septal leads with a positive AVR, while his bedside echo in the emergency department showed normal LV dimensions with akinetic apical and mid septum, and hypokinetic apical anterior wall with an LVEF of 40-45%. Cath lab team was informed for an emergency procedure and preparation of the patient for an emergency diagnostic and therapeutic PCI was started. In the meantime he suddenly developed cardiac arrhythmias, seen as runs of VT/VF on the cardiac monitor. DC shocks were given as per ACLS guidelines but the patient could not be reverted and therefore died soon thereafter. There was no other mortality at 12 months (Table-II).

## DISCUSSION

Significant LMCA disease is a high-risk lesion that compromises blood flow to approximately 75% of the heart. Its prevalence in patients undergoing coronary angiography is 2.5% to 10%, and typically it coexists with other significant narrowing of the coronary tree. Medical treatment of LM disease has unacceptably high mortality rates.<sup>7,21</sup> Early observational studies demonstrated that long-term prognoses of patients with medically treated LMCA

Table-II: Procedure findings.

Variables	N(%)
Isolated LMCA disease	8(15%)
Osteal LAD involvement	45(84%)
Ventricular Tachycardia during procedure	5(9.4%)
Death	1(1.8%)
Technical success	53(100%)

disease were poor, with 3-year survival rates of 50%.<sup>11</sup>

Traditionally the main mode of treatment for LMCA has been CABG with PCI being reserved for surgically poor candidates. But with the advent of improvement in techniques and drug eluting metallic stents, new interest in treating LMS stenosis with PCI has emerged.

In our study, the patients affected with LMCA which were later treated with PCI had mean age of 55.45±10.275. Whereas in other studies majority of patients presented at an advanced age.<sup>23</sup> This highlights the fact that not only is the disease burden on the Indian subcontinent estimated to be the highest worldwide but there also is a markedly earlier progression of disease within the resident population.<sup>22</sup>

In our study the frequency and percentage of patients suffered from unstable angina were 22 (43.1%) with all normal base line investigations. Similarly, the percentage of unstable angina was 46 in the study conducted by Lee et al.<sup>23</sup>

In our study we had one mortality at 3 months which is in line with other studies done in this regard.<sup>24</sup> In a comparable study conducted in 2013 by Ng W et al showed 11 cardiac deaths (1 in-hospital and the remainder beyond 30 days).<sup>4</sup> In our study we do not have any significant adverse effects on follow-up of our patients, other studies also reported a very low incidence of adverse effects post PCI.<sup>24</sup>

The limitation of this study is that we do not have a long term follow up beyond 12 months to document long term safety. Secondly this was not a randomized controlled trial to compare the two techniques namely PCI versus CABG. Nevertheless this is one of the initial studies of its kind from this region clearly showing good technical success as well as short term safety of PCI in LMS.

## CONCLUSION

Our study showed that PCI to LMCA has good technical success rate; the short term safety of the procedure is also acceptable. The result suggests potential need for a large, multicenter, randomized

study with long-term follow up to provide a basis for re-evaluation of treatment guidelines for the treatment of left main coronary artery disease.

## REFERENCES

1. El-Menyar AA, Al Suwaidi J, Holmes JDR. Left main coronary artery stenosis: state-of-the-art. *Curr Prob Cardiol.* 2007;32:103-193.
2. Eagle KA, Guyton RA, Davidoff R, Edwards FH, Ewy GA, Gardner TJ, et al. ACC/AHA 2004 guideline update for coronary artery bypass graft surgery: a report of the American College of Cardiology/American Heart Association Task Force on Practice Guidelines (Committee to Update the 1999 Guidelines for Coronary Artery Bypass Graft Surgery). *Circulation.* 2004;110:e340-e437.
3. Smith SC Jr, Feldman TE, Hirshfeld JW Jr, Jacobs AK, Kern MJ, King SB III, et al. ACC/AHA/SCAI 2005 guideline update for percutaneous coronary intervention: a report of the American College of Cardiology/ American Heart Association Task Force on Practice Guidelines (ACC/AHA/SCAI Writing Committee to Update 2001 Guidelines for Percutaneous Coronary Intervention). *Circulation.* 2006;113:e166-e286.
4. Ng W, Lundstrom R, McNulty E. Impact of stenting technique and bifurcation anatomy on long-term outcomes of PCI for distal unprotected left main coronary disease. *J Invasive Cardiol.* 2013;25(1):23-27.
5. Naik H, White AJ, Chakravarty T, Forrester J, Fontana G, Kar S, et al. A meta-analysis of 3,773 patients treated with percutaneous coronary intervention or surgery for unprotected left main coronary artery stenosis. *J ACC Cardiovasc Interv.* 2009;2(8):739-747.
6. Ferrante G, Presbitero P, Valgimigli M, Morice MC, Pagnotta P, Belli G. Percutaneous coronary intervention versus bypass surgery for left main coronary artery disease: a meta-analysis of randomised trials. *Euro Intervention.* 2011;7(6):738-746.
7. Garner WL, Stoler RC, Laible EA, Kang MJ, Choi JW. Percutaneous coronary artery stenting of unprotected leftmain coronary artery disease using drug-eluting stents: the initial Baylor University Medical Center experience. *Proc (Bayl Univ Med Cent).* 2007;20(4):339-343.
8. Chieffo A, Stankovic G, Bonizzoni E, Tsagalou E, Iakovou I, Montorfano M, et al. Early and mid-term results of drug-eluting stent implantation in unprotected left main. *Circulation.* 2005;111(6):791-795.
9. Price MJ, Cristea E, Sawhney N, Kao JA, Moses JW, Leon MB, et al. Serial angiographic follow-up of sirolimuseluting stents for unprotected left main coronary artery revascularization. *J Am Coll Cardiol.* 2006;47(4):871-877.
10. Hokken RB, Foley D, van Domburg R, Serruys PW. Left main coronary artery dissection duringpercutaneous coronary intervention treatedby stenting. *Neth Heart J.* 2002;10(10):395-398.
11. Ragosta M, Dee S, Sarembock IJ, Lipson LC, Gimple LW, Powers ER. Prevalence of unfavorable angiographic characteristics for percutaneous intervention in patients with unprotected left main coronary artery disease. *Catheter Cardiovasc Interv.* 2006;68:357.
12. Serruys PW, Morice MC, Kappetein AP, Colombo A, Holmes DR, Mack MJ, et al. Percutaneous coronary intervention versus coronary-artery bypass grafting for severe coronary artery disease. *N Engl J Med.* 2009;360:961.
13. Fajadet J, Chieffo A. Current management of left main coronary artery disease. *Eur Heart J.* 2012;33(1):36-50.
14. Kandzari DE, Colombo A, Park SJ. Revascularization for unprotected left main disease: Evolution of the evidence basis to redefine treatment standards. *J Am Coll Cardiol.* 2009;1576-1588.
15. Buszman PE, Kiesz SR, Bochenek A. Acute and late outcomes of unprotected left main stenting in comparison with surgical revascularization. *J Am Coll Cardiol.* 2008;538-545.
16. Pandya SB, Kim YH, Meyers SN, Davidson SJ, Flaherty JD, Park D et al. Drug-Eluting Stents versus Bare Metal Stents in Unprotected Left Main Coronary Artery Stenosis: a Meta-Analysis. *JACC Cardiovasc Interv.* 2010;3(6):602-611.
17. Awan MA, Khan A, Siddiqi TA, Hussain A, Rabbi F, Tasneem H. Early effects of coronary artery bypass grafting on left ventricular regional wall motion abnormalities. *J Coll Physicians Surg Pak.* 2007;17(1):3-7.
18. Biondi-Zoccai GG, Lotrionte M, Moretti C, Meliga E, Agostoni P, Valgimigli M, et al. A collaborative systematic review and meta-analysis on 1278 patients undergoing percutaneous drug-eluting stenting for unprotected left main coronary artery disease. *Am Heart J.* 2008;155(2):274-283.
19. White AJ, Kedia G, Mirocha JM, Lee MS, Forrester JS, Morales WC, et al. Comparison of coronary artery bypass surgery andpercutaneous drug-eluting stent implantation for treatment of left main coronary artery stenosis. *JACC Cardiovasc Interv.* 2008;1:236-245.
20. Cheng CI, Wu CJ, Fang CY, Youssef AA, Chen CJ, Chen SM et al. Feasibility and safety of transradial stenting for unprotected left main coronary artery stenoses. *Circ J.* 2007;71(6):855-861.
21. Jiang WB, Zhao W, Huang H, Li CL, Zhang JH, Wang Y, et al. Meta-analysis of effectiveness of first-generation drug-eluting stents versus coronary artery bypass grafting for unprotected left main coronary disease. *Am J Cardiol.* 2012;110(12):1764-1772.
22. Patel JV, Dwivedi S, Hughes EA, Lip GY. Premature coronary artery disease: an inferred cardiovascular variant or a South Asian genetic disorder? *Thromb Haemost.* 2008;99(6):991-992.
23. Lee MS, Kapoor N, Jamal F, Czer L, Aragon J, Forrester J, et al. Comparison of Coronary Artery Bypass Surgery With Percutaneous Coronary Intervention With Drug-Eluting Stents for Unprotected Left Main Coronary Artery Disease. *J Am Coll Cardiol.* 2006;47(4):864-870.
24. Capodanno D, Stone GW, Morice MC, Bass TA, Tamburino C. Percutaneous Coronary Intervention Versus Coronary Artery Bypass Graft Surgery in Left Main Coronary Artery Disease. *J Am Coll Cardiol.* 2011;58(14):1426-1432.

---

### Authors:

1. Liaqat Ali, FCPS (Medicine), Department of Cardiology,
2. Shahid Nawaz Malik, MRCP, Interventional cardiologist, Head of Department of Cardiology,
3. Abdullah Bin Khalid, Dow University of Health Sciences, Karachi, Pakistan.
4. Mehboob Sultan, FCPS (Pediatrics), AFIC/NIHD, Rawalpindi, Pakistan.
5. Nadeem Sadiq, FCPS (Pediatrics), 1, 2: Pakistan Institute of Medical Sciences, Islamabad, Pakistan.
- 4, 5: Armed Forces Institute of Cardiology & National Institute of Heart Diseases AFIC/NIHD, Rawalpindi, Pakistan.