



Histomorphological and Biochemical Effects of Ethanolic Extract of *Monodora myristica* Seed (African Nutmeg) on Some Liver Function Parameters Using Albino Wistar Rats

P. Akpojotor^{1*} and H. D. Kagbo²

¹Department of Human Physiology, University of Port Harcourt, Nigeria.

²Department of Pharmacology, University of Port Harcourt, Nigeria.

Authors' contributions

This work was carried out in collaboration between both authors. Author PA designed the study, carried out the administration of extract, collected the samples and tissues for laboratory analysis, did the statistical analysis and wrote the first draft of the manuscript. Author HDK did the extract extraction, determination of administered dose and formulation of the stock solution. Final manuscript was done by both authors.

Article Information

DOI: 10.9734/BJMMR/2016/27521

Editor(s):

(1) Chan-Min Liu, School of Life Science, Xuzhou Normal University, Xuzhou City, China.

Reviewers:

(1) G. Bupesh, Sree Balaji Medical College and Hospital, India.

(2) Asante Du-Bois, University of Cape Coast, Ghana.

(3) Samuel Ifedioranma Ogenyi, Nnamdi Azikiwe University, Nnewi Campus-Nigeria.

(4) Normadiyah M. Kassim, University of Malaya, Malaysia.

Complete Peer review History: <http://www.sciencedomain.org/review-history/16718>

Original Research Article

Received 6th June 2016
Accepted 17th October 2016
Published 5th November 2016

ABSTRACT

Aim: This study was carried out to investigate the effects of *Monodora myristica* on the physiological status of the liver using albino Wistar rats as a model.

Study Design: This research was conducted at the Department of Human Physiology, Faculty of Basic Medical Sciences, University of Port Harcourt, Nigeria; between May and October, 2014.

Methodology: Thirty six (36) albino Wistar rats weighing between 180 – 220 g were used in the study. They were grouped into 3 groups of 12 rats each (2 test groups and a control group). The animals were fed with standard feed and clean water. In addition, those of test groups 2 and 3 also received 400 mg/kg and 200 mg/kg of ethanolic extract of *M. myristica* seed respectively on daily

*Corresponding author: E-mail: Peghosen4life@yahoo.com;

basis for twenty eight days (four weeks). After each week of administration, three rats from each group were sacrificed, blood samples collected by cardiac puncture for biochemical analysis of some liver function parameters (alkaline phosphatase (ALP), alanine transaminase (ALT), aspartate aminotransferase (AST), serum total protein and serum albumin). The liver of the animals were also examined for histological study.

Results: The results from the biochemical assay were subjected to statistical analysis and it showed a significant ($p < 0.05$) increase in ALT values, non significant increase in AST and ALP values, and a non significant effect on total serum protein and serum albumin. The histological study of the liver showed hepatocytes and periportal inflammations as well as cytoplasmic swelling, which are indications of alteration on the normal physiological status of the liver.

Conclusion: Findings from this study showed that the extract produced an adverse alteration in the normal histomorphology and biochemical make-up of the liver. Therefore, the plant should be used with caution, especially when used for medicinal purposes.

Keywords: *Ethanollic extract; Monodora myristica; liver enzymes; hepatocytes and physiological status.*

1. INTRODUCTION

The use of medicinal plants as therapy for health conditions is an age long practice [1]. This usage has gained prominence worldwide over the last three decades and has been estimated that at present over two third of the developing countries' population relies on plant preparation as medicines to take care of their health needs [2]. This surge in the use of medicinal plants as therapy is believed to be due to their accessibility and affordability and the perceived failure of synthetic drugs in the treatment of some chronic diseases like hypertension, diabetes, arthrosclerosis etc. [2]. According to Akerele [3], about 65-80% of the world's population in developing countries, due to poverty and lack of access to modern medicine, depend essentially on plants and their formulations for their primary health care.

Medicinal plants and their formulations have continued to attract attention as a result of the strong speculations and belief that they are safe and very efficacious [4,5]. This strong speculation and assumption has led to the indiscriminate use of medicinal plants and their formulations especially in developing countries, like Nigeria [1].

M. myristica is a species of plant which belong to the family of Annonaceae [6]. *M. myristica* forms a large branching tree with a gray-barked trunk and reach 35 m high in nature. It has large leaves (35 cm long and 18 cm wide) at the end of its branches. The leaves are purple at first but turn a smooth deep green on the upper side with paler green underneath. They are prominently veined and the petiole is purplish [7]. This is widely distributed from Africa to Asia, Central and

South America and Australia [8,9]. It is native to Central, East and West Africa [10]. *M. myristica* grows very well in the ever green forest of West Africa and in Nigeria are most prominent in the Southern part [11,12]. Its common names include; Calabash nutmeg, African nutmeg, False nutmeg, Jamaican nutmeg, while its local names include Ehuru or Ehiri (Igbo), Ariwo (Yoruba) [8], Erhe (Urhobo), Ehinawosin (Ikale), Uyengben (Edo) [10]. *M. myristica* seed is oblongoid in shape and pale brown in colour with a thin seed coat and hard kernel. Phytochemically, *M. myristica* seeds have been reported to contain secondary metabolites like saponins, tannins, flavonoids, glycosides, alkaloids and steroids [12-14]. They also contain minerals like potassium, sodium, magnesium, phosphorus and iron [12]. They have also been reported to contain amino acids like phenylalanine, tyrosine, arginine, glutamic acid, asparagines, vitamin C and E, and sugars [15,16]. *M. myristica* has been used as herbal plant and spices since ancient times. It is used in the treatment of hemorrhoids, stomach ache, fiber pain, constipation [17,8]. And also to control passive uterine hemorrhage after childbirth [18,19,8]. It has also been associated with antisickling effectiveness [16]. As spices, the seeds are grinded and used in cooking pepper soup and stew [12,20]. The seeds are also used as an aromatic and stimulating addition to medicines and snuff. In Central African Republic, the seeds are used as condiment and drug in the treatment of headache and hypertension [21]. The direct action of these plant extracts is on the liver, which is central to drug metabolism [22].

The liver is the largest internal and very vital organ in the body, constituting about 2.5% of an adult's body weight. The liver plays an important

role in maintaining blood glucose levels. It also regulates the circulating blood lipids by the amount of very low density lipoproteins (VLDLs) it secretes. Liver takes up numerous toxic compounds and drugs which may include medicinal plant formulations from the portal circulation [23]. Many drugs and metabolites are hydrophobic, the liver converts them into hydrophilic compounds and in the process some may adversely affect the liver. Such drugs or metabolites are said to be hepatotoxic, and their effects on the liver are determined by measuring the plasma concentration of some biochemical compounds and enzymes called the liver markers, produced by the liver. These liver markers include total serum protein, albumin, triglycerides, total cholesterol, high and low density lipoproteins, and liver enzymes like alkaline phosphatase, aspartate transaminase and alanine transaminase, etc.

Presently, some research studies have showed that some of these used medicinal plants adversely affect some vital organs in the body while exhibiting their therapeutic potentials [24]. Consequently, it has become imperative to ascertain the effects of plants used as herbs on the physiological status of vital organs. Hence, the objective of this study to investigate the effects of the ethanolic extract of *M. myristica* seed (African Nutmeg) on the physiological status of the liver using albino Wistar rats.



Fig. 1. Fruit (pod) and seeds of African nutmeg

2. METHODS

2.1 Study Design

This research was conducted at the Department of Human Physiology, Faculty of Basic Medical Sciences, University of Port Harcourt, Choba, Nigeria; between May and October, 2014.

2.2 Experimental Animals

Thirty six (36) male albino Wistar rats weighing (180 – 220 g) were purchased and kept at the animal house, Department of Human Physiology, College of Health Sciences, University of Port Harcourt, Rivers State, Nigeria. The animals were kept in a spacious and well ventilated cage (2feet length by 1foot width by 1foot height) for each group, and at room temperature (25 – 29°C); under 12 hours light and dark cycle and acclimatize for 14 days. They were allowed free access to feed (Top Feeds, Broiler finisher – Product of Eastern premier feed mills Ltd.) and water *ad libitum*.

Ethical clearance was obtained from the Research Ethics Committee of the Center for Research Management and Development (CRMD), University of Port Harcourt. All animal experiments were conducted in compliance with NIH guidelines for Care and Use of Laboratory Animals as contained in Guide for the Care and Use of Laboratory Animals 8th edition [25].

2.3 Collection and Identification of Plant Materials

Dried seeds of *M. myristica* were purchased from Abacha Market along Udu road, Udu LGA., Delta State. The plant sample was correctly identified and authenticated in the Herbarium Unit of the Department of Plant Science and Biotechnology, University of Port Harcourt, with Ecoland Herbarium identity number: EH - P – 011, EH – C - 011.

2.4 Preparation of Ethanolic Extracts of *Monodora myristica* Seed

The ethanolic extract of *M. myristica* seeds was prepared according to Akinwunmi and Oyedapo [8]. The seeds of *M. myristica* were dehulled (the coat removed), and rid of bad seeds and dirt. Thereafter, the seeds were milled to fine powder using manual engine grinder (Model Corene, A.5 lander YCIA S.A). The milled sample of the plant

were soaked in 5 L of 80% ethanol for 48 hours, thereafter filtered with Whatman No. 1 filter paper to separate the filtrate from the residue. The filtrate was concentrated under reduced pressure in a vacuum at 45°C using a rotary evaporator (Searl Instruments Ltd. England) into the ethanolic extract used in the study.

2.5 Experimental Design

Thirty six (36) male albino Wistar rats weighing (180 – 220 g) were randomized into three (3) groups of 12 rats each. Group I served as the Control, and received water and normal feed only. Group II received 400 mg/kg of the extract in addition to water and feed. Group III received 200 mg/kg in addition to water and feed. The doses of the extract (400 mg/kg and 200 mg/kg) were chosen based on a previous work that determined the LD₅₀ of *M. myristica* seed to be >5000 mg/kg [26]. The extract was daily administered via oral route between 8 am to 10 am throughout the period of administration.

Three rats from each group were sacrificed after every seven days, that is, on day 8, day 15, day 22 and day 29 days. After each sacrifices, blood was collected by cardiac puncture into lithium heparin tubes for biochemical analysis, while the liver of each rat was collected via abdomino-thoracic dissection into plain tubes containing buffered formalin for histological study.

2.6 Biochemical Parameters

The collected blood samples were centrifuged at 5000 rpm for 10 minutes to obtain clear serum for the biochemical analysis. The serum supernatant was then carefully aspirated with needled syringe and stored in a plain sample tubes for biochemical analysis. The biochemical analysis for serum alanine aminotransferase (ALT), serum aspartate aminotransferase (AST), serum alkaline phosphatase (ALP), total serum protein and serum albumin were done using

Mindray Auto-analyzer machine (Model: BS – 800M) in the laboratory of the Department of Chemical Pathology at the University of Port Harcourt Teaching Hospital following standard laboratory procedures.

2.7 Histopathological Examination

Histopathological examination was done following the method outlined previously [27]. Harvested organ (liver) from each animal were cut and fixed in buffered neutral formalin (10%). The tissues were dehydrated in ascending grades of ethanol (70%, 80%, 90%, 95% and 100%), cleared in 2 changes of Xylene, impregnated with 2 changes of molten paraffin wax, and finally embedded in wax. Tissue sections of 4–5 µm in thickness were cut with a microtome and stained with hematoxylin and eosin.

2.8 Statistical Analysis

The data were statistically analyzed using SPSS VERSION 20.0, and was analyzed for statistical significance by one way Analysis of Variance (ANOVA) followed by Dunnett's post-test for comparison with control group. P values less than 0.05 were considered to indicate statistical significance.

3. RESULTS

The result of serum ALT concentrations of rats administered 400 mg/kg and 200 mg/kg doses of the ethanolic extract of *M. myristica* is presented in Table 1. The result showed a dose dependent significant $p < 0.05$ increase in the test groups in comparison with the control group.

The result of serum AST concentrations of rats administered 400 mg/kg and 200 mg/kg doses of the extract is presented in Table 2 above. The result showed a non significant $p > 0.05$ increase in the test groups in comparison with the control group.

Table 1. Effects of ethanolic extracts of *M. myristica* on serum ALT (IU/L) in albino

Groups	ALT (IU/L) week 1	ALT (IU/L) week 2	ALT (IU/L) week 3	ALT (IU/L) week 4
Control	72.67±8.76	76.28±4.18	71.73±6.34	69.97±2.88
400 mg/kg <i>M. myristica</i>	197.33±42.08*	198.00±4.73*	212.67±7.27*	205.00±15.18*
200 mg/kg <i>M. myristica</i>	162.67±32.2*	146.00±7.77	198.33±112.10*	154.67±2.33*

Values are expressed as Mean±SEM; n=12; *: Significant at $p < 0.05$

The effects of 400 mg/kg and 200 mg/kg doses of the extract on serum ALP of rats is presented in Table 3. The result showed a non significant increase in the test groups in comparison with the control group.

The results of serum total protein and serum albumin of rats administered 400 mg/kg and 200 mg/kg doses of the extract are presented in Tables 4 and 5 respectively. The results showed non significant effects.

4. DISCUSSION

This study is aimed at investigating the effects of ethanolic extract of *Monodora myristica* on the

physiological status of the liver using albino Wistar rats as models. *Monodora myristica* is a species of plant which belong to the family of Annonaceae [6]. This plant has been associated with different medicinal usage. It is used in the treatment of hemorrhoids stomach ache, fiber pain, and constipation [18,9]; control passive uterine hemorrhage after childbirth [19,20] and has also been associated with antisickling effectiveness [17]. The seeds are also used as an aromatic and stimulating addition to medicines and snuff [7,28]. In Central African Republic, the seeds are used as condiment and drug in the treatment of headache and hypertension [22].

Table 2. Effects of ethanolic extracts of *M. myristica* on serum AST (IU/L)

Groups	AST (IU/L) week 1	AST (IU/L) week 2	AST (IU/L) week 3	AST (IU/L) week 4
Control	323.33±22.85	333.45±8.47	325.63±19.65	320.43±21.58
400 mg/kg <i>M. myristica</i>	501.67±204.6	388.33±54.23	480.67±26.59	632.33±88.89
200 mg/kg <i>M. myristica</i>	328.33±141.21	378.33±6.89	383.67±511.36	432.67±37.55

Values are expressed as Mean ± SEM; n=12; *, Significant at p<0.05

Table 3. Effects of ethanolic extracts of *M. myristica* on serum ALP (IU/L)

Groups	ALP (IU/L) week 1	ALP (IU/L) week 2	ALP (IU/L) week 3	ALP (IU/L) week 4
Control	298.33±18.32	293.72±06.24	289.94±14.12	298.33±12.98
400 mg/kg <i>M. myristica</i>	326.33±41.86	312.00±14.93	353.67±34.37	356.00±89.50
200 mg/kg <i>M. myristica</i>	321.00±134.97	294.00±14.57	317.00±151.24	307.67±11.20

Values are expressed as Mean±SEM; n=12; *, Significant at p<0.05

Table 4. Effects of ethanolic extracts of *M. myristica* on serum total protein (g/L)

Groups	Total protein (g/L) week 1	Total protein (g/L) week 2	Total protein (g/L) week 3	Total protein(g/L) week 4
Control	64.00±0.58	65.03±1.35	62.14±0.33	65.32±0.29
400 mg/kg <i>M. myristica</i>	62.67±2.60	65.00±2.08	65.67±3.84	63.33±2.73
200 mg/kg <i>M. myristica</i>	61.67±1.20	66.00±1.73	64.33±4.70	59.33±4.06

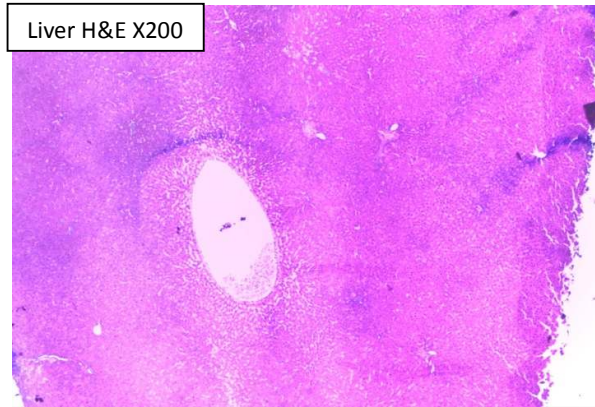
Values are expressed as Mean±SEM; n=12; *, Significant at p<0.05

Table 5. Effects of ethanolic extracts of *M. myristica* on serum albumin (g/L)

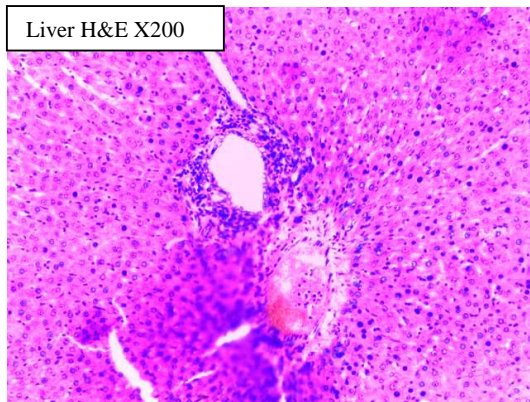
Groups	Albumin (g/L) week 1	Albumin (g/L) week 2	Albumin (g/L) week 3	Albumin (g/L) week 4
Control	29.00±0.58	29.68±0.18	30.00±0.47	33.53±1.08
400 mg/kg <i>M. myristica</i>	34.00±1.53	30.00±0.58	27.67±0.67	33.00±1.73
200 mg/kg <i>M. myristica</i>	31.33±1.45	30.33±0.67	26.33±3.48	30.67±0.88

Values are expressed as Mean±SEM; n=12; *, Significant at p<0.05

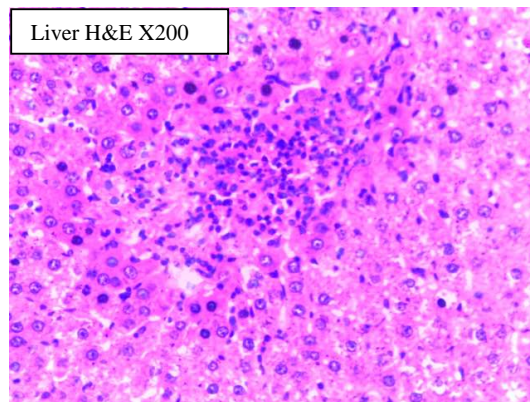
Photomicrograph of liver from experimental animals



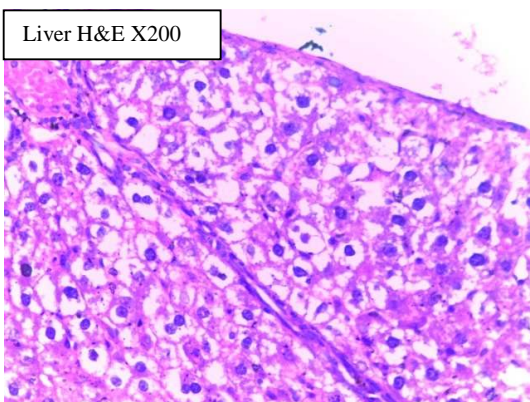
A: Showing normal histology of liver with No inflammatory cells



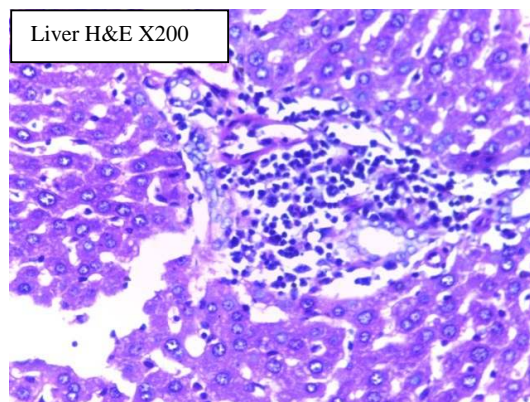
B: Showing mild hepatocytes and periportal inflammation



C: Showing increase degree of inflammation compared to (B)



D: Showing severe inflammation cytoplasmic swelling



E: Showing severe hepatocyte and periportal degeneration

Fig. 2. Photomicrographs of liver of the various groups. A. Normal control group, B. Test group treated with 200 mg/kg *M. myristica* for one week, C. Test group treated with 400 mg/kg *M. myristica* for one week, D. Test group treated with 200 mg/kg *M. myristica* for four weeks, E. Test group treated with 400 mg/kg *M. myristica* for four weeks

Following some present studies showing that some of the commonly used medicinal plants negatively alters the physiological status of other vital organs of the body in the process of discharging their desired medicinal effects [1] [25], hence this study. The physiological status (functionality or health state) of the liver is mainly determined by measuring the plasma levels of some enzymes called the liver enzymes which include alkaline phosphatase (ALP), aspartate transaminase (AST) and alanine transaminase (ALT), etc [6,29] and other biochemicals produced by the liver which include total serum protein, albumin, bilirubin, triglycerides, total cholesterol, high and low density lipoproteins, etc. Normally ALT and AST are mainly present and in high concentrations within the liver cells (hepatocytes), damage or destruction of the hepatocytes leads to the release of these enzymes into circulation thereby increasing their plasma levels [30]. Thus, increase in the plasma or serum level of any of these enzymes is an indication of hepatocytes damage. ALP is an enzyme in the cell lining of the biliary ducts of the liver. Its plasma level increases when liver bile duct obstruction is present or there is intrahepatic cholestasis or infiltrative diseases [31].

The result from the biochemical analysis of this study showed that the 400 mg/kg and 200 mg/kg dose of the extract significantly ($p < 0.05$) increased the serum ALT, and in a dose dependent manner (Table 1). This increase is an indication of liver (hepatocytes) damage which may have resulted to the release of ALT from the damaged hepatocytes into blood circulation, as has been reported by previous works [6,29]. This result was supported by the histological study of the harvested liver which shows hepatocytes and periportal inflammations of varying degree as well as cytoplasmic swelling. These negative effects may have occurred as a result of metabolism of the extract by the liver which serves as the primary organ of biotransformation [32] and also agree with the theory of target organ toxicity [33].

Though, both administered doses cause general increase in the serum AST and ALP, but the increase was not significant as shown in Tables 2 and 3. However, this may indicate delayed effect since histological examination of the liver indicated the presence of hepatocytes inflammation and degeneration; periportal inflammation and hepatocytes fatty accumulations (fatty changes).

From the results, it was observed that the ethanolic extract of *M. myristica* do not have any effect on the total serum protein and albumin as shown in Tables 4 and 5.

The histological study of the harvested liver shows that the ethanolic extract of *M. myristica* negatively alters the physiological status of the liver in a dose and time dependent manner, as various degrees of hepatocytes and periportal inflammation and degeneration was observed.

5. CONCLUSION

This study reveals that *Monodora myristica* seed (at its medicinal doses) shows negative effects on the anatomical physiology of the liver. Therefore, we advised that caution should be taken in employing their medicinal effects. However, these findings only serve as a template for further studies to ascertain the biochemical components of the plant responsible for this impairment of the liver and their mechanism of actions.

CONSENT

It is not applicable.

COMPETING INTERESTS

Authors have declared that no competing interests exist.

REFERENCES

1. Mbaka CO, Adeyemi OO, Oromosu AA. Acute and subchronic toxicity studies of the ethanolic extract of the leaves of *Sphenocentrum jollyyanum* (Menispermaceae). *Agric. Biol. J N Am.* 2010;1(3):265-272.
2. Okpuzor J, Ogbunugafor HA, Kareem GK. Hepatic and hematologic effects of fractions of *Globimetula braunii* in normal albino rats. *EXCLI Journal.* 2009;8:182-189.
3. Akerele O. Summary of WHO guidelines for the assessment of herbal medicines. *Herbal Gram.* 1993;28:13-19.
4. Said O, Khalil K, Fulder S, Azaizeh H. Ethnobotanical survey of medicinal herbs of the Middle Eastern region. *J. Ethnopharmacol.* 2002;83:251-265.
5. Farnsworth NR, Soejarto DD. Potential consequence of plant extinction in the

- United States on the current and future availability of prescription drugs. *Econ Bot.* 1985;39:231-240.
6. Ekeanyanwu RC, Njoku OU. Acute and subacute oral toxicity study on the flavonoid rich fraction of *Monodora tenuifolia* seed in albino rats. *Asian Pacific Journal of Biomedicine.* 2014;4(3):194-202.
 7. Barwick M. *Tropical and subtropical trees; a worldwide encyclopaedic guide.* Thames and Hudson, London; 2004.
 8. Akinwunmi Femi Feyisayo, Oyedepo Oluboade Oluokun. Evaluation of antioxidant potentials of *Monodora myristica* (Gaertn) seed seeds. *African Journal for Food Science.* 2013;7(9):317-324.
 9. Omobuwajo TO, Omobuwajo OR, Sanni LA. Physical properties of calabash nutmeg (*Monodora myristica*) seeds. *J. Food Eng.* 2003;57:375-381.
 10. Keay RWJ. *Trees of Nigeria.* Claridon Press Oxford. 1989;11(3):5.
 11. Adegoke E, Akinsanya A. Studies of Nigerian medicinal plants. *J. West Afr. Sci. Assoc.* 1970;13(2):15-65.
 12. Basse ME, Johnny II, Okoro BI. Lesser known spices of Akwa Ibom; their nutritional, antinutritional, mineral and phytochemical analysis. *Archives of Applied Science Research.* 2011;3(3):553-559.
 13. Uhegbu FO, Iweala EJ, Kanu I. Studies on the chemical and anti nutritional content of some Nigerian spices. *Inter. J. Nutri. Metab.* 2011;3(6):72-76.
 14. Ekeanyanwu RC, Etienajirhevwe OF. *In vitro* antihelmintic potentials of *Xylopiya aethiopia* and *Monodora myristica* from Nigeria. *Afr. J. Biochem. Res.* 2012; 6(9):115-120.
 15. Nwachukwu N. Nutritional and antinutritional substances in some selected indigenous spices. Ph.D Thesis, FUTO, Nigeria; 2000.
 16. Uwakwe AA, Nwaoguikpe RN. *In vitro* antisickling effects of *Xylopiya aethiopia* and *Monodora myristica* on sickle cell blood. *Journal of Medicinal Plant Research.* 2008;2(6):119-124.
 17. Gill LS. *Ethnomedical uses of plants in Nigeria.* University of Benin Press, Benin city, Nigeria. 1992;165:248.
 18. Nwaoguikpe RN, Ujowundu CO, Emejulu AA. The antioxidant and free radical scavenging effects of extracts of seeds of some neglected legumes of South-East Nigeria. *Sch. Acad. J. Biosci.* 2014;2(1): 51-59.
 19. Okafor JC. Edible indigenous woody plants in the rural economy of the Nigerian forest zone. *Forest Ecology and Management.* 1981;3:48-55.
 20. Okafor JC. Development of forest tree crops for food supply in Nigeria. *Forest Ecology and Management.* 1987;1:235-247.
 21. Koudou J, Etou Ossibi AW, Aklikokou K, Abena AA, Gbeassor M, Bessiere JM. Chemical composition and hypotensive effects of essential oil of *Monodora myristica* Gaertn. *Journal of Biological Sciences.* 2007;7(6):937-942.
 22. Guyton A, Hall JA. *Textbook of medical physiology.* 9th Edition; W.B. Saunders's Company; 1996.
 23. Maton Anthea, Jean Hopkins, Charles McLaughlin, Susan Johnson, Maryanna Warner, David LaHart et al. *Human biology and health.* Englewood Cliffs, New Jersey, USA: Prentice Hall; 1993. ISBN: 0-13-981176-1
 24. Chan K. Some aspect of toxic contaminants in herbal remedies. A review. *Chemosphere.* 2003;52:1361-1371.
 25. Committee for the update of the guide for the care and use of laboratory animals, Institute for laboratory animal research, Division on earth and life studies. *Textbook on Guide for the Care and Use of Laboratory Animals.* 8th Edition, National Academies Press, Washington D.C. ISBN: 978-0-309-15401-7
 26. Ezenwali MO, Njoku OU, Okoli CO. Studies on the anti-diarrheal properties of seed extract of *Monodora tenuifolia*. *International Journal of Applied Research in Natural Products.* 2010;2(4):20-26.
 27. Mosaid AZ. Toxicity induced histological changes in selected organs of male (Wistar) rats by *Lawsonia inermis* Leaf Extract. *European Journal of Medicinal Plants.* 2012;2(2):151-158.
 28. Ekeanyanwu RC, Njoku O, Ononogbu IC. The phytochemical composition and some biochemical effects of Nigerian Tignut (*Cyperus esculentus* L.) tuber. *Pakistan Journal of Nutrition.* 2010;9(7):709-715.
 29. Aliyu R, Adebayo AH, Catsing D, Garba IH. The effects of ethanolic extract leaf of *Commiphora africana* (Burseraceae) on rat

- liver and kidney function. J. Pharmacol Toxicol. 2006;2:373-379.
30. Bupesh G, Amutha C, Subramanian P, et al. Hepatoprotective activity of red algae *H. muciformis* against experimentally induced hepatotoxicity in albino rats. Brazilian Journal of Biology and Technology. 2016;89:1509-1607.
31. Angelico F, Del-Ben M. Toward predicting therapeutic response in patients with hepatitis C: author's reply. Ailment Pharmacol Ther. 2010;31:339-340.
32. Sani D, Sanni S, Sandabe UK, Ngulde SI. Toxicological studies on *Anisopus mannii* crude aqueous stem extract: Biochemical and histopathological effects in albino rats. International Journal of Pharmaceutical Sciences. 2010;2(1):51-59.
33. Heywood R. Target organ toxicity. Toxicol. Lett. 1981;8:349-358.

© 2016 Akpojotor and Kagbo; This is an Open Access article distributed under the terms of the Creative Commons Attribution License (<http://creativecommons.org/licenses/by/4.0>), which permits unrestricted use, distribution, and reproduction in any medium, provided the original work is properly cited.

Peer-review history:
The peer review history for this paper can be accessed here:
<http://sciencedomain.org/review-history/16718>